

## Evaluation of Nephroprotective Effect of Carica Papaya Root Extract in Paracetamol Induced Nephrotoxicity in Experimental Rats

Ramdas Bhat, Sameena, Ravikumar

Assistant Professor, Department of Pharmacology, Karavali College of Pharmacy, Vamanjoor(post), Mangalore, Karnataka, India- 575028

Assistant Professor, Department of Pharmacology, Karavali College of Pharmacy, Vamanjoor(post), Mangalore, Karnataka, India- 575028

Principal, Karavali College of Pharmacy, Mangalajyothi, Vamanjoor (post), Mangalore, Karnataka, India, - 575028

Submitted: 10-05-2022

Accepted: 20-05-2022

### ABSTRACT:

The purpose of this study is to evaluate if a hydroalcoholic root extract of Carica papaya has any nephroprotective qualities in Wistar rats with paracetamol-induced nephrotoxicity (PCM). When used in excessive doses, paracetamol (PCM), an analgesic and antipyretic, can cause liver and kidney necrosis in humans and animals. The animals were put into four groups of six each. The purpose of this study was to look into the effects of Carica papaya hydroalcoholic extract [200 mg/kg and 400 mg/kg] on Paracetamol-induced nephrotoxicity. For 7 days, the first group was given distilled water as a control, while the other groups were given Paracetamol alone (750 mg/kg), Paracetamol+200 mg/kg extract, and Paracetamol+400 mg/kg extract. Treatment with HACP root extract at doses of 200mg/kg and 400mg/kg prevented kidney damage caused by Paracetamol and free radical induced kidney damage, as well as a significant decrease in weight of kidney, blood urea level, blood creatinine level, urinary glucose level, and urinary potassium level, as well as an increase in body weight, volume of urine, urine creatinine level, and total blood protein level. HACP substantially increased tissue GSH while decreasing lipid peroxidation. Histological observations confirmed that HACP therapy restored the degenerative effects of paracetamol. Finally, these above findings indicated that HACP has nephroprotective properties against kidney damage induced by Paracetamol.

**KEYWORDS:** Hydroalcoholic extract of Carica papaya root (HACP), Paracetamol (PCM), Nephrotoxicity, Kidney.

### I. INTRODUCTION:

The kidneys are the main organ of the urogenital system. It performs the important function of removing unwanted wastes resulting from the breakdown of blood proteins from the renal artery by small filtering units called nephrons<sup>[1]</sup>. Kidney disease affects people all over the world, regardless of age, ethnicity, environment or geography. The Etiology behind the complication is broad, ranging from substance-induced to various metabolic and physiological disorders, and nephropathy is one of the top 10 major causes of death in the world.<sup>[2,3,4]</sup> Acute renal failure (ARF) where there is a loss of kidney functions for a shorter duration and the functionality can be reversed back after few days or weeks. There are many causes of acute renal failure, including mainly acute tubular necrosis, which usually accounts for 85% of the incidence. Most often, acute tubular necrosis occurs due to ischemia or toxins. Toxins can be exogenous or endogenous. Exogenous agents are X-ray contrast agent, immunosuppressants like cyclosporine, antibiotics, chemotherapeutic agents, various organic solvents and paracetamol, and illegal abortifacients. Chronic kidney failure (CKD) is an irreversible decline in renal function that often occurs over time and resulting in the loss of metabolic and endocrine clearance functions. Variety of causes of renal failure have been identified, including hypertension, diabetes, antineoplastic drugs such as cyclophosphamide, vincristine, and cisplatin, among others.<sup>[5,6]</sup> The traditional systems of treatment such as Ayurveda, Unani, Siddha, western herbal medicine, Traditional Chinese

medicine and homeopathy use herbs for the treatment [7].

*Carica papaya* is a Caricaceae family member with the popular name papaya. The fruit is a huge berry that is normally spherical or cylindrical in shape and is 15 to 45 cm (5.9 to 17.7 in) in length and 8 inches in diameter. When it is ripe, its skin becomes amber to orange in colour, and numerous black seeds are stuck to the walls of the big central cavity [8]. *Carica papaya* has important components in varying concentrations throughout the plant, including its fruits, leaves, roots, and seeds. *Carica papaya* is primarily composed of phenolic acids, with chlorogenic acid appearing in low concentrations in comparison to flavonoids and coumarin components [9]. The fruits and roots contain important vitamins, flavonoids and various other minerals. The ripened fruit serves to be a very good source nutrients such as vitamins A, Vitamin C and Calcium [10].

So, the present study was done to evaluate Nephroprotective activity of *Carica papaya* roots as it has various active constituents so as to minimize the side effects caused by synthetic drugs and to promote the use of a novel natural medicinal plant.

## II. MATERIALS AND METHODS

The *Carica papaya* roots was procured from Pilikula Nisargadhama, Vamanjoor, Mangalore and it was authenticated by botanist Dr. Siddaraju M N. M.Sc. PhD Assistant professor, Department of Botany, University College, Mangalore. The current study was carried out at Karavali College of Pharmacy in Mangalore, in the Department of Pharmacology.

### ANIMALS

The study employed Wister rats weighing 150-200 g. The experimental animals were fed a standard pelleted diet (Lipton India Ltd., Mumbai) and distilled water ad libitum. The temperature was kept constant at 210°C-230°C with a 12-hour light and dark cycle. Before conducting the experiment, all animals were acclimatized to laboratory condition for 5 days. All experiments were done after following the guidelines on ethical standards for investigation of nephroprotective activity in experimental rats.

### PLANT EXTRACT

The roots were shade dried at room temperature. A mechanical grinder was used to crush the dried material into coarse powder. Using a Soxhlet extraction device, the resultant powder was extracted directly with 70% v/v ethanol. Under reduced pressure, the extract was asked to

concentrate. Finally, it was placed in a desiccator for future use.

## III. DETERMINATION OF ACUTE TOXICITY (LD50) [11]

The procedure was divided into two phases. Phase I (observation on the first day) and Phase II (observed the animals for next 14 days of drug administration). For this experiment, two groups of three healthy female rats were used. The first set of animals were divided into three groups, each with one animal. The animals were fasted overnight and given water as needed. Animals were given a single dosage of 2000 mg/kg, p.o. for the test because the test item was an herb source. Food was withheld for 3-4 hours following the administration of the extract.

## IV. EFFECT OF HACP ON PARACETAMOL INDUCED NEPHROTOXICITY IN RATS [12]

The albino rats were divided in to 4 groups and each group contains 6 rats and treatment would be as follows

**Group I:** These animals received only normal saline through i.p route throughout the trial and served as the normal control.

**Group II:** For 7 days, the animals in this group were administered acetaminophen suspension by p.o at a dose of 750 mg/kg.

**Group III:** This group's animals were administered 200 mg/kg, p.o HACP and 750 mg/kg of paracetamol suspension via p.o after one hour. The HACP was given to the animals for seven days.

**Group IV:** This group's animals were administered 400 mg/kg p.o HACP and paracetamol suspension via p.o at a dose of 750 mg/kg after one hour of administration of test dose. The HACP was given to the animals for seven days.

All of the animals for collecting the urine sample were now placed in metabolic cages for the next 24 hours, and on the eighth day, the rats were sacrificed under moderate ether anaesthesia, and kidney tissues, urine, and blood samples were collected and analysed.

## PHYSICAL ELEMENTS WEIGHT OF THE BODY

In paracetamol-induced nephrotoxicity weight of each animal were noted, and the % change in the body weight was calculated.

### WEIGHT OF THE KIDNEY

In paracetamol-induced nephrotoxicity, the weight of the animals' kidneys at the end of treatment was measured.

### VOLUME OF URINE

In the case of paracetamol-induced nephrotoxicity, the urine volume of the animals was measured.

### BIOCHEMICAL ESTIMATION PARAMETER

The following values are evaluated using normal Excel, Beacon, and TransAsia diagnostics estimating procedures: Sodium, potassium, creatinine, glucose, and other urinary parameters Urea, creatinine, and total protein are blood measures.

### ESTIMATION OF GLUTATHIONE<sup>[13]</sup>

Trichloroacetic acid was used to homogenise tissue samples in a tissue homogenizer. A modified Ellamn technique was used to assay glutathione (Aykae, et.al.) Once centrifugation at 3000 rpm for 10mins was done, for 2 ml of 0.3 M disodium hydrogen phosphate (DHSP) solution, 0.5 ml of obtained supernatant liquid was added. The absorbance at 412 nm was measured immediately after mixing a 0.2 ml dithiobisnitrobenzoate (DTBNB) solution (0.4 mg/ml in 1 % sodium citrate). Glutathione levels increase in proportion to the percentage increase in OD. As a result, the OD increase % is computed.

### LIPID PEROXIDATION<sup>[13]</sup>

Stock solution of TCA-TBA-HCl reagent: 0.375 percent w/v thiobarbituric acid; 0.25 N hydrochloric acid; 15% w/v trichloroacetic acid to aid in the breakdown of the thiobarbituric acid, this solution can be slightly heated. Mix well 1.0 ml of biological material (0.1-2.0 mg membrane protein

or 0.1-0.2 mol lipid phosphate) with 2.0 ml of TCA-TBA-HCl. The solution is now heated for 15 minutes in a boiling water bath. After cooling, the flocculent precipitate was removed by centrifugation at 1000 rpm for 10 minutes. The sample's absorbance is measured at 535 nm in comparison to a blank containing all of the reagents except the lipid. The % reduction in OD is closely related to the reduction in lipid peroxidation levels. As a result, the OD drop is calculated as a percentage.

### STATISTICAL ANALYSIS

The values are expressed as Mean SEM. The data was analysed using graph pad prism programme, which was then one-way ANOVA followed by Dunnett's test. Statistical significance was established at  $P \leq 0.05$ .

## V. RESULT

### EFFECT OF HACP ON CHANGE IN BODY WEIGHT, URINE VOLUME AND KIDNEY WEIGHT

Body weight and urine volume were observed to be lower in the paracetamol-treated group (II). However, it was found that there was dose dependent increase of body weights and urine volume significantly ( $p < 0.001$ ) in animals treated with HACP 200 mg/kg and 400 mg/kg, p.o ( $p < 0.001$ ) (III and IV) when compared with group (II) (Table No.1) The kidney weight increased in the paracetamol-treated group (II). When compared to the group (II), there was a substantial dose-dependent decrease in kidney weight in animals treated with HACP 200 mg/kg p.o ( $p < 0.001$ ) and 400 mg/kg p.o ( $p < 0.001$ ) (III and IV) (II). (Table No.1)

**Table No.1: Effect of Hydroalcoholic Carica papaya root extract on Change in Body Weights, Urine Volume and Kidney Weight in Paracetamol Induced Nephrotoxic Rats.**

GROUP	DOSE	CHANGE IN BODY WEIGHTS (g)	URINE VOLUME (ml)	KIDNEY WEIGHT (g)
I	Vehicle	8.760± 0.7556	4.533± 0.2008	0.6120± 0.0250
II	Paracetamol 750 mg/kg p.o	-8.760± 0.2702	3.133± 0.3059	0.9467± 0.0257
III	Paracetamol 750 mg/kg p.o + 200 mg/kg p.o HACP	-4.765± 0.2155***	5.113± 0.2275***	0.6233± 0.0162***
IV	Paracetamol 750 mg/kg p.o + 400	-2.457± 0.1326***	6.150± 0.2760***	0.6017± 0.0144***

	mg/kg p.o HACP			
--	----------------	--	--	--

Values are Mean ± SEM (n=6) one way ANOVA followed by Dunnett's test. Where, \*\*\*P<0.001, \*\*P<0.01, \*P<0.05 and ns represents Not significant. All values are compared with Toxicant control. HACP: Hydro alcoholic extract of Carica papaya.

**EFFECT OF HACP ON URINARY SODIUM, POTASSIUM, GLUCOSE AND CREATININE**

There was a decrease in sodium levels in the paracetamol-treated group (II) compared to the control (I). However, 200 mg / kg, p.o. (III) HACP and 400 mg / kg, p.o. (IV) HACP has no significant effect on sodium levels in urine samples compared to group (II). (Table 2) Potassium levels in the paracetamol-treated group (II) were increased compared to the control group (I). However, 200 mg / kg p.o. (III) HACP increased potassium levels

slightly but not significantly. For 400mg / kg p.o. HACP (IV) significantly reduced the potassium levels observed in urine samples compared to group (II) (p <0.001). (Table 2) Glucose levels in the paracetamol-treated group (II) were increased compared to the control group (I). However, 200 mg / kg, p.o. HACP (III) glucose levels were significantly (p <0.001), 400 mg / kg, p.o. HACP (IV) significantly reduced glucose levels in urine samples compared to group (II) (p <0.001). (Table 2) Urinary creatinine levels in the paracetamol-treated group (II) were decreased compared to the control group (I). However, if the HACP (III) creatinine level is significantly (p <0.05), 400 mg / kg p.o. HACP (IV) was observed to have a significant increase in creatinine levels (p <0.001) in the urine sample when compared to group (II). (Table 2)

**Table No. 2: Effect of HACP on Urinary Sodium, Potassium, Glucose and Creatinine Levels in Paracetamol Induced Nephrotoxic Rats.**

TABLE NO. 2: EFFECT OF HACP ON URINARY SODIUM, POTASSIUM, GLUCOSE AND CREATININE LEVELS IN PARACETAMOL INDUCED NEPHROTOXIC RATS. GROUP	TREATMENT	URINARY SODIUM LEVELS (mCPmol/l)	URINARY POTASSIUM LEVELS (mmol/l)	URINARY GLUCOSE LEVELS (mg/dl)	URINARY CREATININE LEVELS (g/L)
I	Vehicle	196.1± 3.485	4.169± 0.2410	1.343± 0.1290	3.283± 0.2554
II	Paracetamol 750 mg/kg p.o	129.4± 2.325	7.268± 0.4655	32.72± 2.0119	0.9625± 0.1772
III	Paracetamol 750 mg/kg p.o + 200 mg/kg p.o HACP	126.3± 1.309ns	5.825± 0.3415ns	13.15± 0.9107***	1.851± 0.1079*
IV	Paracetamol 750 mg/kg p.o + 400 mg/kg p.o HACP	121.0± 1.719ns	3.749± 0.3905***	7.781± 0.7451***	2.485± 0.3680***

Values are Mean ± SEM (n=6) one way ANOVA followed by Dunnett's test. Where, \*\*\*P<0.001, \*\*P<0.01, \*P<0.05 and ns represents Not significant. All values are compared with Toxicant

control. HACP: Hydro alcoholic extract of Carica papaya.

**EFFECT ON BLOOD UREA AND BLOOD CREATININE AND BLOOD TOTAL PROTEIN**

Blood urea levels were increased in the paracetamol-treated group (II) compared to the control group (I). However, 200 mg / kg and 400 mg / kg p.o. HACP (III and IV) significantly increased urea levels in blood samples ( $p < 0.001$ ) compared to group (II). (Table 3) Blood creatinine levels were increased in the paracetamol-treated group (II) compared to the control group (I). 200 mg / kg po HACP (III) slightly reduced blood

creatinine levels but not significantly, 400 mg / kg p.o. HACP (IV) compared to group (II) blood samples Significantly reduced creatinine levels in ( $p < 0.01$ ). (Table 3) In the paracetamol-administered group (II), the total blood protein level was lower than that in the control group (I). 200 mg / kg, po where HACP (III) significantly increased total protein levels ( $p < 0.001$ ), 400 mg / kg, p.o. HACP (IV) significantly increased total protein levels in blood samples compared to group (II) ( $p < 0.001$ ). (Table 3)

**Table No. 3: Effect of HACP on Blood Urea, Blood Creatinine and Blood Total Protein Levels in Paracetamol Induced Nephrotoxic Rats.**

TABLE NO. 3: EFFECT OF HACP ON BLOOD UREA, BLOOD CREATININE AND BLOOD TOTAL PROTEIN LEVELS IN PARACETAMOL INDUCED NEPHROTOXIC RATS. GROUP	TREATMENT	BLOOD UREA (mg/dl)	BLOOD CREATININE (mg%)	BLOOD TOTAL PROTEIN (g/dl)
I	Vehicle	49.29±2.012	1.567±0.2414	6.322±0.0738
II	Paracetamol 750 mg/kg p.o	79.73±2.162	2.591±0.3896	2.891±0.3561
III	Paracetamol 750 mg/kg p.o + 200 mg/kg p.o HACP	47.99±2.231***	2.029±0.3873ns	5.145±0.3235***
IV	Paracetamol 750 mg/kg p.o + 200 mg/kg p.o HACP	32.33±1.430***	1.054±0.0636**	6.047±0.3016***

Values are Mean ± SEM (n=6) one way ANOVA followed by Dunnett's test. Where, \*\*\* $P < 0.001$ , \*\* $P < 0.01$  and \* $P < 0.05$ . All values are compared with Toxicant control. HACP: Hydro alcoholic extract of Carica papaya.

**EFFECT OF HACP ON TISSUE LIPID PEROXIDATION (LP) AND GLUTATHIONE (GSH)**

There was dose dependent inhibition of in-vivo LP by both the doses of HACP. 200 mg/kg p.o HACP showed 30.90% inhibition, whereas 400 mg/kg, p.o HACP showed 53.89% inhibition. There was a marked depletion of GSH level in paracetamol treated groups. HACP showed a dose dependent increase in the level of GSH. However, at 200 mg/kg, p.o HACP showed 47.99% increase in GSH level and 400 mg/kg p.o HACP showed 20.64% increase in GSH levels.

**Table No. 4: Effect of HACP on Tissue LP and GSH Levels in Paracetamol Induced Nephrotoxicity Model.**

GROUP	DOSE	ABSORBANCE (LP)	% INHIBITION (LP)	ABSORBANCE (GSH)	% INCREASE (GSH)
I	Vehicle	0.2647± 0.0081	–	1.625± 0.1157	–
II	Paracetamol 750 mg/kg, p.o	0.8220± 0.0219	–	0.8487± 0.0461	–
III	Paracetamol 750 mg/kg, p.o + 200 mg/kg, p.o HACP	0.5683± 0.0109***	30.901	1.289± 0.0369*	47.996
IV	Paracetamol 750 mg/kg, p.o + 400 mg/kg, p.o HACP	0.3797± 0.0066***	53.893	1.521± 0.0887***	20.64

Values are Mean ± SEM (n=6) one way ANOVA followed by Dunnett’s test. Where, \*\*\*P<0.001, \*\*P<0.01, \*P<0.05 and ns stands for not significant. Toxicant control is used to compare all values. HACP: Carica papaya hydroalcoholic extract.

**Histopathological Study Of Kidneys In Paracetamol Induced Nephrotoxicity**

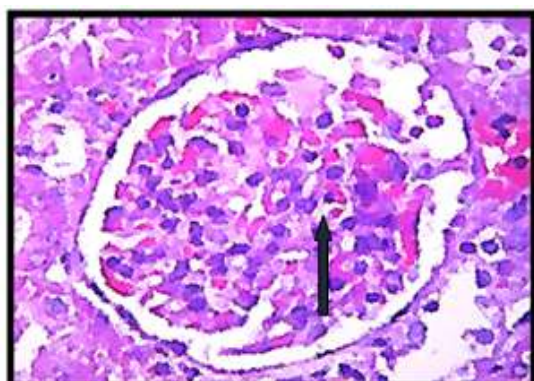
**Group I:** The renal parenchyma architecture was intact in the negative control. Arrow+ bowman's space and mesangial cells were visible in the glomerulus \*Fig. 1. There were intact renal tubules [Fig. 2, Arrow], blood arteries, and interstitial space.

**Group II:** The intact architecture of the renal parenchyma was seen in the positive control. In the glomerulus [Fig.1, Short - Arrow+ : Bowman's space seems reduced, erythrocyte extravasation and

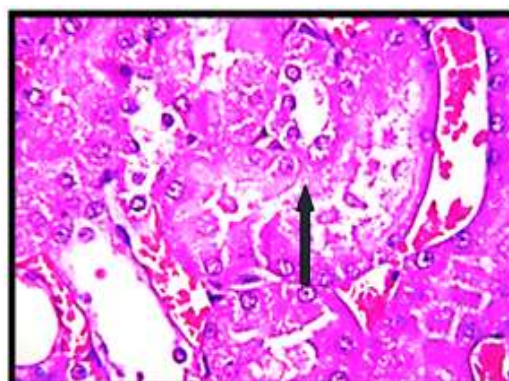
mesangial cells appear enhanced. Few renal tubules reveal degenerative alterations [Fig.2, Arrow]. The interstitial space and blood arteries were unremarkable.

**Group III:** The renal parenchyma architecture was intact after treatment with HACP 200 mg/kg p.o. \*Fig. 1, Arrow+: Glomerulus Bowman's space looks to be intact, with erythrocyte extravasation and intact mesangial cells. The bulk of the renal tubules [Fig.2, Arrow] are degenerating. There are only minor blood vessels and interstitial space visible.

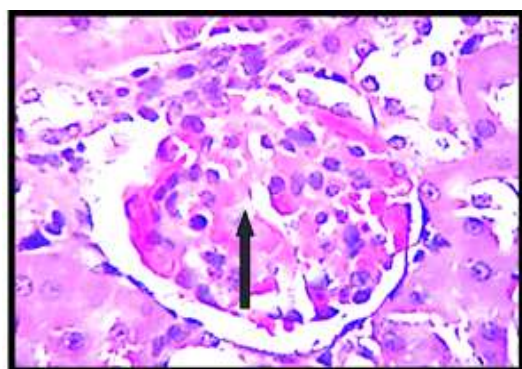
**Group IV:** Treatment with HACP 400 mg/kg p.o. revealed intact renal parenchyma architecture. Glomerulus intact [Fig.A, arrow]. Intact renal tubules and certain tubules display degenerative alterations [Fig.2, Arrow]. Blood vessels and interstitial space remained unremarkable.



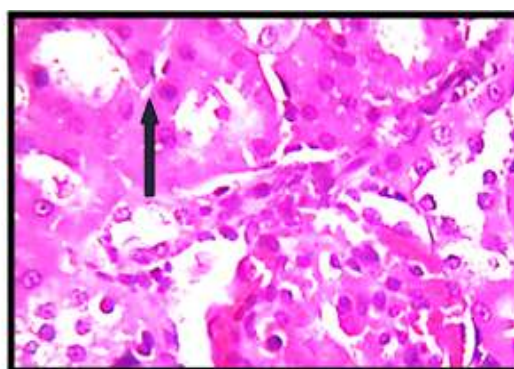
**Group-I (Fig. 1)**



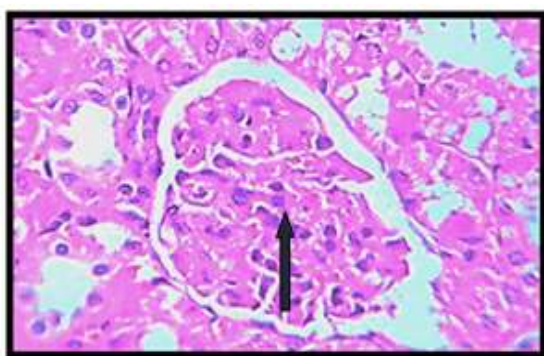
**Group-I (Fig.2)**



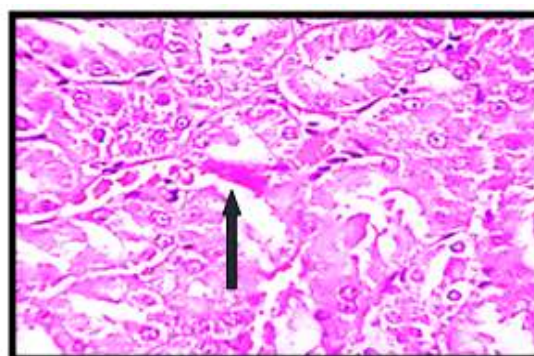
Group-II (Fig. 1)



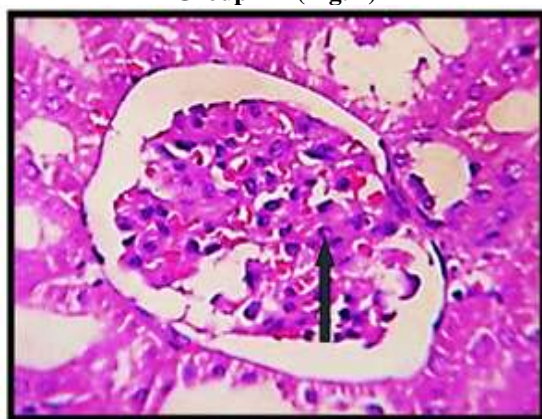
Group-II (Fig. 2)



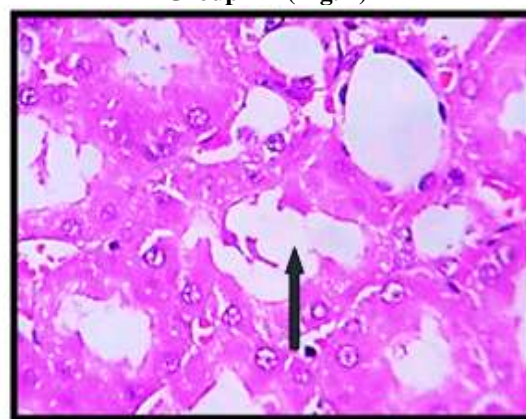
Group-III (Fig. 1)



Group-III (Fig. 2)



Group-IV (Fig. 1)



Group-IV (Fig. 2)

Figure No. 1: Histopathology of Kidney

## VI. DISCUSSIONS

Environmental toxins, clinically valuable medications such as acetaminophen and gentamicin, and notably pharmaceuticals used to treat cancer and certain disorders such as tuberculosis can all induce severe organ toxicity. The majority of these nephrotoxic medications have been linked to kidney damage as a result of free radical production. As a result, the produced free radicals outperform the built-in defensive mechanism, resulting in nephrotic damage and

necrosis [14]. Plants have a wide range of free radical scavenging molecules, such as phenolic compounds (flavonoids, coumarins, lignans, quinones, tannins, stilbenes), nitrogen compounds (alkaloids, amines), vitamins, terpenoids (including carotenoids), and some other endogenous metabolites. Natural antioxidants have been linked to a lower frequency of organ damage [15].

In this study, we established that giving rats 750 mg/kg PCM for seven days in a row could cause nephrotoxicity. Concurrent administration of

a hydro-alcoholic extract of *Carica papaya* roots with PCM reduced PCM-induced nephrotoxicity. A dose of 750 mg/kg PCM increased kidney weight, urinary potassium, urinary glucose, blood urea, and blood creatinine while decreasing body weight, urine volume, urinary sodium, urinary creatinine, and blood total protein. It also reduced GSH levels while increasing LP levels. The histological evidence revealed that the architecture of the renal parenchyma was intact, erythrocyte extravasation was seen in the glomerulus, bowman's gap appeared diminished, mesangial cells were larger, and the majority of the renal tubules showed degenerative alterations.

In this study, we showed that giving rats 750 mg/kg PCM for seven days in a row could cause nephrotoxicity. Concurrent administration of a hydro-alcoholic extract of *Carica papaya* roots reduced PCM-induced nephrotoxicity. The oral administration of 750 mg/kg PCM increased kidney weight, urinary potassium, urinary glucose level, blood urea level, and blood creatinine level while reducing the body weight, urine volume, urinary sodium level, urinary creatinine level, and blood total protein content. It also decreased GSH levels while increasing LP levels. The histological evidence revealed that the architecture of the renal parenchyma was intact, extravasation of erythrocytes in the glomerulus, bowman's gap seems diminished, mesangial cells appear expanded, and the majority of the renal tubules show degenerative alterations.

The HACP contains alkaloids, flavonoids, saponins, terpenoids, and tannins, all of which have antioxidant activity. Antioxidant activity may play a role in organ protection. As a result, the antioxidant principle of HACP can be linked to its antioxidant and organ-protective capabilities. Our investigation found that HACP was efficient in protecting against acetaminophen-induced kidney injury; however, the specific mechanism is unknown.

More research is needed to explain and appreciate how HACP acts to mitigate the nephrotoxic effect of acetaminophen.

## VII. CONCLUSION

According to the physical measurements, biochemical condition, and histological findings, administration of HACP root extract has nephroprotective potential against paracetamol-induced Nephrotoxicity. The HACP enhanced GSH levels in deficient tissues and decreased lipid peroxidation caused by paracetamol-induced

nephrotoxicity. The most notable effects were noticed when the HACP extract was administered at 400 mg/kg as opposed to a lesser dose of the extract at 200 mg/kg. The presence of antioxidant principles and phytochemical elements in HACP could explain why the 70% hydro-alcoholic extract of *Carica papaya* roots possesses nephroprotective properties.

## CONFLICT OF INTEREST:

No conflict of interest.

## REFERENCES

- [1]. Ramesh K, Manohar S, Rajeshkumar S. Nephroprotective activity of ethanolic extract of *Orthosiphon stamineus* leaves on ethylene glycol induced urolithiasis in albino rats. *J Pharm Tech Res.* 2014; 6:403-08.
- [2]. Coresh J, Astor BC, Greene T, Eknoyan G, Levey AS. Prevalence of chronic kidney disease and decreased kidney function in the adult US population: Third National Health and Nutrition Examination Survey. *American journal of kidney diseases.* 2003 Jan 1;41(1):1-2.
- [3]. National Kidney Foundation. Fact Sheets [Internet]. National Kidney Foundation. 2014. Available from: <https://www.kidney.org/news/newsroom/fsindex>
- [4]. Go AS, Chertow GM, Fan D, McCulloch CE, Hsu CY. Chronic kidney disease and the risks of death, cardiovascular events, and hospitalization. *New England Journal of Medicine.* 2004 Sep 23;351(13):1296-305.
- [5]. Bauer C, Melamed ML, Hostetter TH. Staging of chronic kidney disease: time for a course correction. *Journal of the American Society of Nephrology.* 2008 May 1;19(5):844-6.
- [6]. Schlondorff DO. Overview of factors contributing to the pathophysiology of progressive renal disease. *Kidney international.* 2008 Oct 1;74(7):860-6.
- [7]. Veeresh BD, Ramesh K, Bhatt K. Evaluation of Hepatoprotective activity of *Jasminum sambac* in rats. *Int. J. Res. Pharmacol. Pharmacother.* 2017; 6:104-16.
- [8]. The Editors of Encyclopaedia Britannica. *papaya* | Description, Cultivation, Uses, & Facts | Britannica. In: *Encyclopædia Britannica* [Internet]. 2021. Available from: <https://www.britannica.com/plant/papaya>





- [9]. Canini A, Alesiani D, D’Arcangelo G, Tagliatesta P. Gas chromatography–mass spectrometry analysis of phenolic compounds from *Carica papaya* L. leaf. *Journal of food composition and analysis*. 2007 Nov 1;20(7):584-90.
- [10]. Silva JD, Rashid Z, Nhut DT, Sivakumar D, Gera A, Souza MT, Tennant P. Papaya (*Carica papaya* L.) biology and biotechnology. *Tree and Forestry science and biotechnology*. 2007;1(1):47-73.
- [11]. OECD Guidelines for the Testing of Chemical. Acute Oral Toxicity – Up and Down Procedure (UDP) 2001. (Cited 01-20-2012). Available from: <http://iccvam.niehs.nih.gov/SuppDocs/FedDocs/OECD/OEC Dtg425.pdf>.
- [12]. Zariyantey Abdul Hamid, Siti Balkis Budin, Ng Wen Jie, Asmah Hamid, Khairana Husain, Jamaludin Mohamed. *J Zhejiang Univ Sci B* 2012;13(3):176-185.
- [13]. Pramod Kumar, Devala Rao G, Lakshmayya, Ramachandra Setty S. *Avicenna J Med Biotech* 2011;3(2):87-93.
- [14]. Giness JE, Proctor PH, Demopaulos HB, Hockanson JA. *Physiol Chem Physu* 1978;10(3):267-77.
- [15]. Jain PK, Agrawal RK. *Asian J Exp Sci* 2008;22(3):213-220.