

## Formulation and Evaluation of Oral Gel from *Oscimum Sanctum* Extract for Treatment of OSMF

Mr. Mayur R. Marewad<sup>1</sup>, Mr. Krishna J. Biradar<sup>2</sup>, Dr. Omprakash G. Bhusnure<sup>1\*</sup>, Padmaja S. Giram<sup>3</sup>

<sup>1</sup>Department of Quality Assurance, <sup>2</sup>Department of Pharmaceutics, <sup>3</sup>Department of Pharmacology  
Channabasweshwar Pharmacy College, Kava Road, Latur – 413512, Maharashtra, India.

\*Corresponding author: Prof. Dr. Omprakash G. Bhusnure, M. Pharm, Ph.D. Professor and  
Head Channabasweshwar Pharmacy College, Department of Quality Assurance, Kava Road, Latur-413512, Dist.  
Latur. (MS)

Submitted: 01-07-2022

Accepted: 08-07-2022

### ABSTRACT

Oral submucous fibrosis (OSMF) is a high risk precancerous condition characterized by changes in the connective tissue fibers of the lamina propria and deeper parts leading to stiffness of the mucosa and restricted mouth opening. The exact etiology of OSMF is still obscure, though various etiologic factors are being mentioned such as genetic, autoimmune, nutritional and environmental; the areca nut chewing habits has been associated with OSMF. *Ocimum sanctum* L. possesses anti-inflammatory, analgesic, antipyretic, antidiabetic, hepatoprotective, hypolipidemic, antistress, and immunomodulatory activities. Preclinical studies have also shown that Tulsi and some of its phytochemicals eugenol, rosmarinic acid, apigenin, myretenal, luteolin,  $\beta$ -sitosterol, and carnolic acid prevented chemical-induced skin, liver, oral, and lung cancers and to mediate these effects by increasing the antioxidant activity, altering the gene expressions, inducing apoptosis, and inhibiting angiogenesis and metastasis. Gels are typically semi-solid formulations having a liquid phase that has been thickened with other components. Gels are formulated by using polymer, preservatives and pH adjuster. Carbopol, Methyl paraben and Triethanolamine are used as polymer, preservative and PH adjuster in oral gel.

**Keywords:** oral submucous fibrosis, *oscimum sanctum*, antioxidant, Carbopol.

### I. INTRODUCTION

#### Tongue<sup>[1,2]</sup>

Tongue is commonly identified as the organ of taste. It also benefits to articulate speech. The secondary functions of the tongue are to help swallowing and chewing the food. Tongue is made up of many muscles. The upper surface contains the taste buds that act as the primary organ

of taste. The tongue's upper surface is also covered with numerous lingual papillae. Saliva keeps the tongue moist, which is necessary to keep it sensitive, and is abundantly supplied with nerves and blood vessels. The tongue also serves as a natural means of cleaning the teeth. The tongue is the only visible part of the digestive tract and therefore, considered as the mirror that reflects the conditions of the body's internal organs, particularly the organs of digestion and metabolism. The tongue also reflects the overall digestive, nutritive and metabolic conditions of the entire organism. It can prove to be a key factor in determining many conditions and the overall health of the body.

Healthy tongue is free of any discomfort such as pain, stinging, burning, swelling or numbness. It is moist, with a rough surface and has an evenly colored pink surface overlaying pale red. Through its sense of taste, the tongue signals to the body, particularly to the digestive organs, to secrete the digestive juices that help the digestion. For example, the taste of fried food signals to the liver and gall bladder to release bile in order to digest its fat.

#### Examination of Tongue

It is easy to examine the tongue in a conscious patient, but difficult in unconscious patients, non-co-operative patients and children. In small children tongue may be examined by gently pressing mental protuberance with index finger and gradually opening the mouth, the baby will protrude the tongue automatically, of course, it is a knack that can be gained by experience.

Examination of the tongue coat yields information on imbalances prevailing in the body, particularly in the digestive tract. It also provides information on the overall state of the patient's

digestion and metabolism, as well as the presence of toxins, or metabolic wastes, generated by faulty or deficient digestive enzymes. Generally, the tongue body portrays conditions that are more deep seated, systemic or chronic, whereas the tongue coat portrays conditions that are more acute, transient or superficial.

Tongue body texture, its shape, size, color, moisture, coating, nature of papillae and the movements are the important components of the tongue examination.

### 1. Tongue Body Texture

Look for the general texture of the tongue body - is it smooth or rough, ruffled or flat. In Greek medicine, the general texture of the tongue body indicates deep-seated, systemic conditions of dryness or wetness prevailing in the organism. Basically, roughness or dryness indicates a Dry temperament, whereas smoothness and wetness indicate a Wet temperament. If the tongue is also swollen or enlarged, this indicates that the body is retaining excess fluids, that body fluid metabolism has become sluggish or obstructed, and fluid excretion deficient. It can also be a sign of a cold, wet Phlegmatic temperament. A dry tongue, especially when accompanied by severe thirst, indicates a condition of dryness in the organism. A ruffled tongue, dimpled with numerous rises, dips, and depressions like a rocky road filled with potholes, generally indicates a sluggish, inefficient digestion and digestive enzymes. Such a tongue will often have a thick, greasy coat, indicating the presence of toxins due to deficient or defective digestive enzymes.

A raw tongue, that looks like a slab of raw meat, and is dark red in color, is generally a sign of advanced consumption, deficiency heat, and a severe depletion of the vital fluids.

A cracked tongue is generally a sign of chronic nervous stress and tension. Most cracks are located on the midline of the tongue, which represents the spinal column.

### 2. Size

A normal, healthy tongue should be sufficiently fleshy and robust, and neither too fat nor too thin. A good feel and understanding for what exactly constitutes normal tongue size comes mainly from the accumulation of clinical experience and observing many different tongues. Basically, diseases or conditions of repletion or excess will present with an enlarged or swollen tongue; the greater the swelling or enlargement, the greater the excess. Usually, this involves an excess

of wetness, or moisture. Conversely, a thin, emaciated tongue indicates a disease or condition of depletion, or deficiency, and a generalized malnourishment of the organs and tissues.

### 3. Color

The overall color of the body of tongue shows the general condition of the blood and the bloodstream, and basic balance of humors and nutrients. A discoloration of the tongue body localized in a particular reflex zone of the tongue indicates an imbalance occurring in its corresponding organ.

The normal color of a healthy tongue is a nice, robust, sanguine pink - a perfectly balanced blend of red and white. Any deviation from this denotes a deviation from this ideal state of health and balance; the greater the deviation, the more severe the imbalance. In order to get a true reading of tongue body color, it's important that inspection of the tongue body be done in a natural, full spectrum light, free from any undue tinting or shading.

**White, Pale:** Generally indicates coldness and deficiency, as well as an excess of cold phlegmatic humors in the bloodstream. This may also indicate anemia or blood deficiency, if supported by other signs and symptoms.

**Red:** Generally indicates an excess of heat in the body - systemic if the whole tongue body is affected, or localized in a particular organ or part if only certain reflex zones are affected. If the tongue is bright red, it indicates more acute or excessive heat. A dark red tongue is often a sign of chronic consumptive or deficiency heat, or a consumptive fever or dyscrasia of the blood. A red, sore, swollen tongue generally indicates an excess of blood.

**Purple:** Indicates either blood stagnation or cyanosis due to a deficiency of vital principles - Vital Force and/or Innate Heat - in the blood. Reddish purple tongue indicates stagnation of the blood and a light purple tongue indicates stagnation of the Vital Force. Purple spots on the tongue indicate a severe stagnation or cancellation of blood in the corresponding organ. Lighter or subtler shades of purple indicate a stagnation of the Vital Force that guides the blood; darker shades of purple indicate a stagnation of the blood itself.

**Yellow:** Generally indicates jaundice, or an excess of bilious, choleric residues backed up into the blood.

**Brown:** Indicates an excess of black bile or melancholic residues in the bloodstream.

### Other Characteristics

- a) Central Cyanosis- Bluish discoloration
- b) Jaundice- Yellowish discoloration
- c) Advanced Uremia- Brown color
- d) Ketosis- Brown discoloration
- e) Riboflavin deficiency- Megaloblastic color
- f) Niacin and some other B complex deficiency- Bright scarlet or beefy red tongue
- g) Severe anemia- pallor

#### 4. Moistness

The moistness of the tongue gives some indication about the state of hydration of the body. Water volume depletion in a person can lead to peripheral circulatory failure characterized by weakness, increased thirst, restlessness, anorexia, nausea, and vomiting, dry and parched tongue. Dryness of the tongue is seen in diarrhea, later stages of severe illnesses, advanced uremia (with brownish discoloration), acute intestinal obstruction, hypovolumic shock and heat exhaustion.

#### 5. The Tongue Coat

The coating or moss on the tongue's surface indicates the current condition of the patient's digestion and metabolism, as well as the presence of toxins and/or morbid, superfluous humours in the body, especially in the digestive tract. Generally, the thicker and heavier the tongue coat, the more severe this build up will be. Some say that the perfectly healthy tongue should show absolutely no coat. Others say that a very small, fine coat, or moss, located in the central stomach area of the tongue, is also permissible in a healthy tongue. It's generally a good idea, as part of an oral hygiene regimen, to scrape off the tongue coating, with a spoon or tongue cleaner in the morning upon arising. If you're going to see a physician for a tongue diagnosis, however, don't scrape that coat off your tongue - leave it there for the doctor to examine.

The astute physician is fully aware that certain strongly colored foods will color the tongue and alter the natural color of its coat. These foods will tend to impart an unnaturally bright or vivid color to the tongue coat, which will usually prompt the physician to inquire about what the patient recently ate or drank.

Basically, tongue coats can vary in four different ways. 1) Thickness or heaviness 2) Color 3) Texture, moisture and consistency 4) Size, location and distribution.

#### Other Characteristics

- a) Enteric fever- Thick white coating

- b) Candidiasis- Sloughing white lesions
- c) Diabetes mellitus and hypo-adrenalism- associated with white sloughing
- d) Secondary syphilis- mucous patches that are painless, smooth, white and glistening, opalescent plaques that cannot be scraped easily
- e) Leukoplakia- Keratotic white patches
- f) HIV infection-airy leukoplakia
- g) Peritonitis- Furring of the tongue
- h) Acute illness - Whit furring

#### 6. Nature of Papillae

(a) Hairy tongue is due to elongation of the filiform papillae which is provoked by poor oral and general health.

Black hairy tongue is a temporary, harmless oral condition that gives the tongue a dark, furry appearance. The distinct look of black hairy tongue usually results from a buildup of dead skin cells on the numerous tiny projections (papillae) on the surface of your tongue that contain taste buds. These papillae, which are longer than normal, can easily trap and be stained by tobacco, food or other substances, and bacteria or yeast.

Although black hairy tongue may look alarming, typically it doesn't cause any health problems and is usually painless. Black hairy tongue usually resolves without medical treatment.

Signs and symptoms of black hairy tongue include:

- Black discoloration of the tongue, although the colour may be brown, tan, green, yellow or white
- A hairy or furry appearance of the tongue
- Altered taste or metallic taste in mouth
- Bad breath (halitosis)
- Gagging or tickling sensation, if the overgrowth of the papillae is excessive.

(b) In geographic tongue, there is irregularly shaped red and white patches resembling a map on dorsal and lateral surfaces. Geographic tongue, also known as benign migratory glossitis or erythema migrans, and is of unknown etiology. Although previous research pointed to associations with diabetes, psoriasis, seborrheic dermatitis, and atopy, recent analysis of population data does not support these findings.

Sharply defined demarcation of inflammation is characteristic in geographic tongue. With geographic tongue, the dorsal tongue develops areas of papillary atrophy that appear smooth and are surrounded by raised serpiginous borders. These regions of atrophy spontaneously resolve and migrate, giving the tongue a variegated appearance. The condition is benign and localized, generally requiring no treatment except

reassurance. Some patients may have sensitivity to hot or spicy food.

### ORAL SUBMUCOUS FIBROSIS

Oral submucous fibrosis (OSF) is a high risk precancerous condition characterized by changes in the connective tissue fibers of the lamina propria and deeper parts leading to stiffness of the mucosa and restricted mouth opening. The exact etiology of OSMF is still obscure, though various etiologic factors are being mentioned such as genetic, autoimmune, nutritional and environmental, the areca nut chewing habits (most common) has been associated with OSMF. In patients with submucous fibrosis, the oral epithelium becomes atrophic and thereby becomes more vulnerable to carcinogens. The atrophic epithelium shows first an intercellular edema and later epithelial atypia associated with moderate epithelial hyperplasia. From then on, carcinoma may develop any time. It is suggested that submucous fibrosis should be regarded as a condition that causes predisposition to the development of oral cancer. Here we are discussing cases of oral submucous fibrosis showing malignant potential and development of oral squamous cell carcinoma.

#### I. Group I: Very early

- Normal mouth opening
- Burning sensation
- Excessive salivation
- Acute ulceration and recurrent stomatitis

#### II. Group II: Early cases

- Mouth opening: 26-35mm (interincisal opening)
- Soft palate and faucial pillars as the areas primarily affected
- Buccal mucosa appears mottled and marbled, with dense, pale, depigmented and fibrosed areas alternating with pink normal mucosa.
- Red erythematous patches
- Widespread sheets of fibrosis

#### III. Group III: Moderately advanced

- Mouth opening: 15-25mm (interincisal opening)
- Trismus
- Vertical fibrous bands can be palpated and are firmly attached to underlying tissue
- Patient unable to puff out the cheeks or whistle
- Lips -atrophy of vermillion border
- Unilateral posterior cheek involvement with only ipsilateral involvement of the faucial pillar and soft palate, and mouth opening reduced to 15-18mm.

#### IV. Group IV (a): Advanced cases

- Stiffness/inelasticity of oral mucosa
- Trismus

- Mouth opening: 2-15mm (interincisal opening)
- fauces thickened, shortened and firm on palpation
- Uvula seen to be involved, as a shrunken, small and fibrous bud
- Tongue movement restricted
- Papillary atrophy (diffuse)
- Lips -circular band felt around entire mouth
- Intraoral examination is difficult

#### V. Group IV (b): Advanced cases with premalignant and malignant changes

- Oral submucous fibrosis and leukoplakia
- Oral submucous fibrosis and squamous cell carcinoma

Precancerous or cancerous changes seen throughout the mucosa. The clinical features of OSMF as follows:

**a) Early OSMF:** Burning sensation in the mouth. Blisters especially on the palate, ulceration or recurrent generalized inflammation of the oral mucosa, excessive salivation, defective gustatory sensation and dryness of mouth.

**b) Advanced OSMF:** Blended and slightly opaque mucosa, fibrous bands in buccal mucosa running in vertical direction. Palate and the faucial pillars are the areas first involved. Gradual impairment of tongue movement and difficulty in mouth opening.

### Oscimum sanctum(Tulsi)

O. sanctum is known as the "Queen of Herbs." It is described as a sacred and medicinal plant in ancient literature and has been used in different formulations for the treatment of a wide range of disorders, including those of the mouth and throat, lungs, heart, blood, liver, kidney, and other systems. It is also called Holy Basil and in Sanskrit Tulsi means "the incomparable one" has got two varieties, Krishna Tulsi (black) and Rama Tulsi (green). O. sanctum has demonstrated antimicrobial, anti-inflammatory effects in various studies.

**Morphology** It is an erect, much branched, fragrant and erected plant attaining a height of about 30-60 cm when mature. Its aromatic leaves are simple, opposite, elliptic, oblong, obtuse or acute with entire or sub serrate or dentate margins, growing up to 5 cm long. The Tulsi flowers are small having purple to reddish color, present in small compact clusters on cylindrical spikes. Stalk less heart-shaped bracts are there at the base of each flower cluster. Sepal cup is not hairy within. Flowers are rarely longer than 5 mm, calyx tube bearded outside near base. Flower tube is hairy. The fruits are small and the seeds yellow to reddish in colour.

### TAXONOMY

Kingdom : Plantae  
Subkingdom : Tracheobionta  
Super division: Spermatophyta  
Division : Magnoliophyta

Class : Magnoliopsida  
Subclass : Asteridae  
Order : Lamiales  
Family : Lamiaceae  
Genus : Ocimum  
Species : O. sanctum



Fig. No. 1: *Ocimum sanctum*(Tulsi)

### PHYTOCHEMICAL DESCRIPTION

Fresh leaves and stem of *Ocimum sanctum* extract yielded some phenolic compounds (antioxidants) such as cirsilineol, circimaritin, isothymusin, apigenin and rosameric acid, and appreciable quantities of eugenol. The leaves of *Ocimum sanctum* contain 0.7% volatile oil comprising about 71% eugenol and 20% methyl eugenol. The oil also contains carvacrol and sesquiterpene hydrocarbon caryophyllene. Two flavonoids orientin and andvicenin from aqueous leaf extract of *Ocimum sanctum* have been isolated.

### Pharmacological Activity

#### 1. Anti-microbial Activity

It showed an antimicrobial effect against *Candida albicans*, *Staphylococcus aureus*, and enteric pathogens. Anti-inflammatory effects are attributed to the compounds present in *O. sanctum* such as Cirsilineol, Cirsimaritin, Isothymonin, Apigenin, Rosavinic acid, linoleic acid, and eugenol. Linoleic acid has the capacity to block both the cyclooxygenase and lipoxygenase pathways of arachidonate metabolism, which is considered to be a good source of beta-carotene, calcium, and Vitamin C. Tulsi contains volatile substances such as estragol, eugenol, linalool, methyl chavicol, methyl cinnamate, cineole, and other terpenes. Studies have shown *Ocimum basilicum* act as a strong antiviral agent against DNA viruses such as herpes virus, adenovirus, and Hepatitis B virus, and RNA viruses. *O. sanctum* seed oil modulates both humoral and cell-mediated immune responses and also it inhibits acute and chronic inflammation by inhibiting cyclooxygenase, lipoxygenase activity, and histamine b and acetylcholine.

#### 2. Anticancer activity

In ayurveda, various plants are used as a potential source of anticancer and antitumor properties. It has been found that ethanolic extract of *Ocimum sanctum* mediated a significant reduction in tumor cell size and an increase in lifespan of mice having Sarcoma-180 solid tumors. Similar results were also obtained by others where leaf extract administered orally (200 mg/kg.) resulted in significant reduction in tumor volume, increase in average body weight, and survival rate of mice. *Ocimum* has the ability to protect the DNA of the body from dangerous radiations.

#### 3. Antidiabetic Activity

*O. sanctum* has been reported to possess very good anti diabetic properties. The anti-diabetic activity of hydroalcoholic extract of *O. tenuiflorum* against streptozotocin and nicotimanide induced diabetes in rats was found to be significant at the dose levels of 250 and 500 mg/kg body weight and this effect was comparable with glibenclamide. Hyperglycaemia was shown to be reduced in a diabetic rats when administered ethanol extract of *O. sanctum* in both acute and long-term feeding studies. In another study by JM A Hannan et al. prominent insulin-secretory effects were noted in the rat pancreas perfused with the ethanol extract and three partition (ethylacetate, butanol and aqueous) fractions of *O. sanctum*. Similar effects were found in acute insulin-release studies using isolated rat islets.

#### 4. Antilipidemic activity

Hyperlipidaemia, atherosclerosis and related diseases are becoming a major health problem now days. Aqueous extract of *O. basilicum* reduces the level of total cholesterol, triglycerides and LDL cholesterol levels in acute



hyperlipidaemia induced by triton WR1339 in rats. In a study conducted on rabbits a diet supplemented with 1-2 % fresh leaves of Tulsi for 28 days lowered the total lipid.

### 5. Antibacterial activity

Antibacterial activity of the aqueous, alcoholic, chloroform extract and oil obtained from leaves of *Ocimum sanctum* were studied against *E. coli*, *P. aeruginosa*, *S. typhimurium* and *S. aureus*. Extract obtained from *O. sanctum* were observed equally effective against pathogenic gram-positive and gram-negative bacteria.

### GEL

Gels are defined as semi rigid systems in which the movement of the dispersing medium is restricted by an interlacing three-dimensional network of particles or solvated macromolecules of the dispersed phase.

The word "gel" is derived from "gelatin," and both "gel" and "jelly" can be drawn back to the Latin *gelu* for "frost" and *gel* are, meaning "freeze" or "congeal." This origin indicates the essential idea of a liquid setting to a solid-like material that does not flow, but is elastic and retains some liquid characteristics. Use of the term "gel" as a classification originated during the late 1800s as chemists attempted to classify semisolid substances according to their phenomenological characteristics rather than their molecular compositions. At that time, analytical methods needed to determine chemical structures were lacking. Introduction The USP defines gels (sometimes called jellies) as semisolid systems containing either suspensions made up of small inorganic particles, or large organic molecules interpenetrated by a liquid.

### Properties of Gel

- Ideally, the gelling agent must be inert, safe and can't react with other formulation constituent.
- It should have suitable anti-microbial agent.
- The gelling agent should produce a sensible solid-like nature at the time of storage which is easily broken when exposed to shear forces produced by squeezing the tube, trembling the bottle or at the time of topical application.
- The topical gel must not be sticky.
- They exhibit the mechanical characteristics of the solid state.
- Each component is continuous throughout the system.
- There is high degree of attraction amongst the dispersed phase and water medium so the gels

remain equally uniform upon standing and doesn't freely settle.

### Application

- Gels are used to achieve optimal cutaneous and percutaneous drug delivery.
- They can avoid gastrointestinal drug absorption difficulties caused by gastrointestinal pH.
- Gels are having property to avoid enzymatic activity and drug interaction with food and drinks.
- They can substitute for oral administration of medication when the route is unsuitable.
- They can avoid the first pass effect, that is, the initial pass of drug substance through the human body.
- They are applied over skin for slow and prolonged absorption.
- Gels have also been applied in pharmacy to some viscous suspension for oral use for example Aluminum hydroxide gel.
- They have localized effect with minimum side effects.

### Advantages of Gels

- Gels are used to achieve optimal cutaneous and percutaneous drug delivery.
- Simple formulation and manufacturing so less investment and cost.
- Improved patient compliance and comfort.
- Reduced dosing frequency.
- Reduced dose concentration improved local bioavailability.
- Ease of administration.

### Characteristics of Gels

#### 1. Swelling

Gels can swell, absorbing liquid with an increase in volume. This can be looked on as the initial phase of dissolution. Solvent penetrates the gel matrix so that gel-gel interactions are replaced by gel-solvent interactions. Limited swelling is usually the result of some degree of cross-linking in the gel matrix that prevents total dissolution. Such gels swell considerably when the solvent mixture possesses a solubility parameter comparable to that of the gellant.

#### 2. Syneresis

Many gel systems undergo contraction upon standing. The interstitial liquid is expressed, collecting at the surface of the gel. This process, referred to as syneresis, is not limited to organic hydrogels, but has been seen in organogels and inorganic hydrogels as well. Typically, syneresis

becomes more pronounced as the concentration of polymer decreases. The mechanism of contraction has been related to the relaxation of elastic stresses developed during the setting of the gel. As these stresses are relieved, the interstitial space available for solvent is reduced, forcing the expression of fluid. Osmotic effects have been implicated, as both pH and electrolyte concentration influence syneresis from gels composed of the ionic gel formers gelatin or psyllium seed gum.

### 3. Ageing

Colloidal systems usually exhibit slow spontaneous aggregation. This process is referred to as ageing. In gels, ageing results in the gradual formation of a dense network of the gelling agent. The inner suggests that this process is similar to the original gelling process and continues after the initial gelation, since the fluid medium is lost from the newly formed gel.

## II. MATERIAL AND METHOD:

### A) Materials:

*Oscimum sanctum* (Tulsi) were obtained as a gift sample from Sun pure extract pvt, Ltd. Other ingredients are Ethanol - Ozone international,

Carbopol 940 Gelling agent - HiMedica Laboratories pvt. Ltd., Pluronic F127 Synthetic Polymer - BASF the chemical company. HPMC K4M - Moly chemie Mumbai, Glycerin - Vikash Pharma Mumbai, Rosemerry oil - Vishal chemie Mumbai, Methyl paraben – international, Propyl paraben - Ozone international, Triethanolamine - Moly chemie Mumbai, Propylene glycol, Moly chemie Mumbai.

### B) Methods:

#### D) Preparation of gel:

##### Cold Method-

1. Preparation of gel containing Tulsi extract & gelling agent of Carbopol 940 soak in water for 2hr.
2. Neutralized with Triethanolamine with continues stirring.
3. Weights of drug dissolve in preweighed propylene glycol with ethanol.
4. Transfer 3 into 1 & agitate for 20min.
5. This dispersion allows hydrating & swell for 60 min adjust pH with the desired pH range is (6.8 to 7.0).
6. During pH adjustment mixture stirred gently with spatula to form homogeneous gel.

### Formulation table:

Sr. No	Ingredients(gm)	F1	F2	F3	F4	F5
1.	Oscimum sanctum (Tulsi)	5	5	5	5	5
2.	Carbopol 940	0.5	1.0	1.5	1.0	-
3.	HPMC K4M	-	-	-	-	2.5
4.	Pluronic F127	-	-	-	20	-
5.	Methyl paraben	0.2	0.2	0.2	0.2	0.2
6.	Propyl paraben	0.1	0.1	0.1	0.1	0.1
7.	Glycerine	5	5	5	5	5
8.	Ethanol	25	25	25	25	25
9.	Rosemerry oil	q.s	q.s	q.s	q.s	q.s
10.	Triethanolamine	q.s	q.s	q.s	q.s	q.s
11.	Propylene glycol (5%)	5	5	5	5	5
12.	Dist. Water (upto)	100	100	100	100	100

Table No. 1: Formulation table

## III. RESULT AND DISCUSSION

### 1. Pre-Formulation Study

#### A. Melting Point:

Melting point of *Oscimum Sanctum* Extract by capillary method was found to be 170-175°C.

#### B. Solubility:

The solubility of *Oscimum Sanctum* Extract was checked in different solvents & was found to be Freely Soluble in Ethanol.

### 2. Standardization of *Oscimum Sanctum* Extract

#### A. Macroscopic characters

1. Colour: white yellow.
2. Odour: Aromatic.
3. Taste: Bitter

#### B. pH values

The mean pH value of 1 % solution of drug *Oscimum Sanctum* was found to be 6.4.

#### C. Ash values

The total ash value, acid insoluble ash value and water soluble ash value were found to be 8.6%, 1%, 4.2% w/w respectively. Ash value is

useful in determining authenticity and purity of Oscimum Sanctum drug and these values are important quantitative standards.




Fig No. 2: Total ash in Tulsi Extract

**Observations:**

Sr. No.	Test	Observation
1	Colour	White yellow
2	Odour	Aromatic
3	Taste	Bitter,
5	pH 1%	6.4
6	Ash value	8.6%

Table No. 2: Standardization of Oscimum Sanctum Extract

**3. FTIR of Oscimum Sanctum gel formulation**

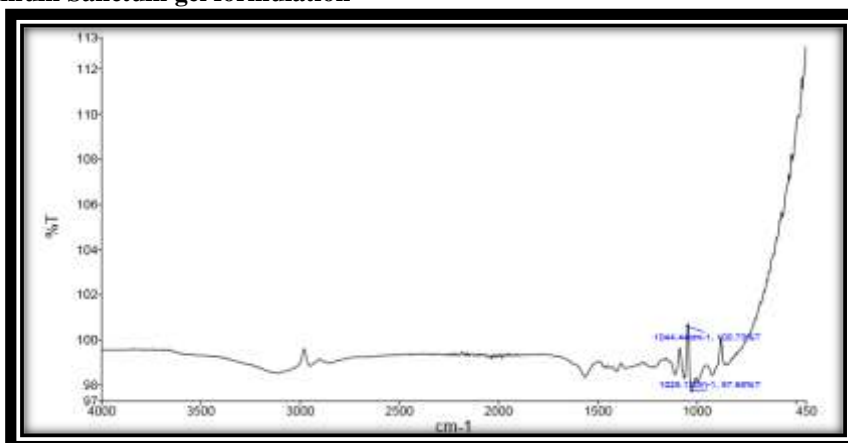


Fig. No. 3: FTIR of Oscimum Sanctum gel formulation

**Interpretation of FTIR of Oscimum Sanctumgel Formulation**

Sr. No.	Functional group	Standard Frequencies	Observed Frequency
1	C-O stretching	1250-1050	1044.44
2	C-N Stretch	1020-1230	1025.12



**Table No. 3: Interpretation of FTIR**

**4. Evaluation of Gel Formulation**

**a). Physical Evaluation:**

Physical Appearance such as colour checked –

Sr.no	Batch	Colour
1	F1	Yellow Gel
2	F2	Yellow Gel
3	F3	Yellow Gel
4	F4	Yellow Gel
5	F5	Yellow Gel

**Table No. 4: Physical appearance such as colour**

**b). Homogeneity:**

All developed gels were tested for homogeneity by visual inspection after the gels have been set in the container

Sr. No.	Batch	Homogeneity
1	F1	Homogeneous
2	F2	Homogeneous
3	F3	Homogeneous
4	F4	Homogeneous
5	F5	Homogeneous

**Table No. 5: Homogeneity of formulation**

**c). pH:**

The pH of various gel formulations were determined by using digital pH meter. 1gm of gel was accurately weighed and dispersed in 10ml of distilled water and stored for two hours.

The measurement of pH of each formulation was carried out in triplicate and the average values are represented. The pH of dispersions was measured using pH meter.

Sr.No.	Batch	pH (%)
1	F1	6.7
2	F2	6.5
3	F3	6.6
4	F4	6.9
5	F5	6.8

**Table No. 6: pH of the formulation**

**d). Consistency:**

Smooth are observed.

glass slide for 5 min to compress the formulation to uniform thickness. Weight 50 gm was added to the pan. The time in seconds require to separate the two slides was taken as measure of spreadability.

**e). Spreadability:**

Formulation placed between two glass slides and 100gm weight was placed on the upper

Sr.No	Batch	Spreadability(g.cm/sec)
1	F1	22.06±1.9
2	F2	27.77±1.3
3	F3	21.13±1.2

4	F4	28.01±1.6
5	F5	26.01±1.8

**Table No. 7: Spreadability of formulation**

**f). Viscosity:**

Viscosity of gel was determined by using Brookfield viscometer at 8, 6, 4 rpm. Each reading was taken after equilibrium of the sample at the end of two minutes. The samples were repeated three times.

Shear rate (RPM)/ST	Viscosity of the formulation in centipoises				
	F1	F2	F3	F4	F5
08	1424	6080	9575	9650	2300
06	1012	3820	18830	3080	4080
04	2435	4960	20700	7533	2435

**Table No. 8: Viscosity of formulation**

**g). Drug Content**

Sr.No	Batch	Drug content (%)
1	F1	95.88±0.78%
2	F2	96.78±0.56%
3	F3	97.55±0.71%
4	F4	98.63±0.63%
5	F5	96.11±0.32%

**Table No. 9: Drug content of formulation**

**h). In-Vitro Diffusion Studies**

Time (min/hr)	% Cumulative Drug release				
	F <sub>1</sub>	F <sub>2</sub>	F <sub>3</sub>	F <sub>4</sub>	F <sub>5</sub>
1	4.43	5.62	6.74	8.3	6.4
2	15.52	16.32	17.45	20.09	19.1
3	26.42	27.3	28.33	32.45	29.2
4	37.36	40.78	42.05	45.47	40.12
5	43.56	49.33	51.18	58.36	52.32
6	59.33	60.31	62.71	69.14	62.51
7	60.4	61.33	63.66	70.85	73.12
8	75.06	78.3	79.6	88.5	85.1

**Table No. 10: In-vitro diffusion study of Oscimum Sanctum[F1-F5].**

In present study or work, an attempt has been made to increase the % drug release of Oscimum Sanctum with changes in concentration of polymers by cold fusion method.

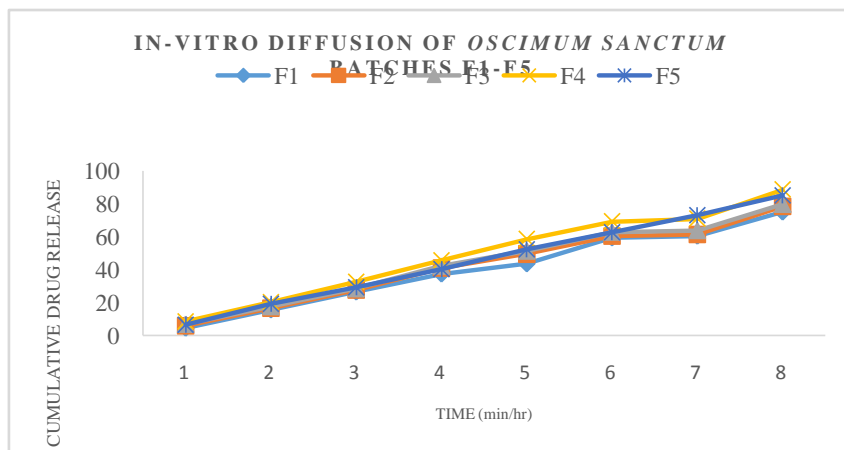


Fig No. 11: In-vitro diffusion of Oscimum Sanctum batches F1-F5.

**i). Stability Study:**

Sufficient quantity of gel formulation were packed in stability container and kept in a Stability chamber at Temperature 40<sup>0</sup>c & RH 75%.

Sr. No	Parameter	Stability after 1 month of a optimized batch	Stability after 2 month of a optimized batch	Stability after 3 month of a optimized batch
1	Colour	Yellow	Yellow	Yellow
2	Physical Appearance	No change	No change	No change
3	Drug Content (%)	98.5%	98.1%	96.7%
4	In vitro drug release	88.5%	88.1%	87.2%
5	pH	6.9%	6.7%	6.5%
6	Consistency	Smooth	Smooth	Smooth

Table No. 12: Stability study of formulation

**IV. SUMMARY**

In the present research work an attempt was made to formulate and evaluate oscimum sanctum extract gel. Standardization of oscimum sanctum extract was done with total ash value, determination of pH etc. the hydroalcoholic extraction was carried out by using ethanol.

To formulate and evaluate Oscimum sanctum extract gel containing polymers like Carbopol, Pluronic F127. The Gel was prepared by cold fusion method. All formulations were checked in PH, Spreadability, Drug content, in-vitro diffusion studies, viscosity, and results were within the limits. The in-vitro diffusion studies were carried out diffusion cell. Among all the formulations (F1 to F5) prepared, batch F4 was the best formulation released 88.5 %.

It is worth to formulate and evaluate the Oscimum Sanctum drug extract in the form of gel

using different polymer for safety, efficacy and better patient compliance as an Oral application.

**V. CONCLUSION**

- Development of Oscimum sanctum extract oral gel helps to improve bioavailability and also minimize side effects.
- Different formulations of Oscimum Sanctum extract, evaluation parameters results were observed, F4 formulation was found to be the best formulation.
- Oscimum Sanctum extract formulation of FTIR studies concluded that there was no interaction between drug and excipient. (Carbopol, Pluronic F127, methyl paraben, Propyl paraben, propylene Glycol, Rosemerry oil.)
- The FTIR studies revealed that, the formulated product is a mixture of drug and the polymers

used, but not the reaction product with the excipient used.

- A good In vitro drug release was observed for formulation F4.

### REFERENCES

- [1]. Schroyens Frederik (2005), Synthesis Repertorium Homeopathicum Syntheticum, B Jain Publisher (P) Ltd. New Delhi 110 055
- [2]. Russ B.E, Prier JE, Rao S, Turner SJ. T cell immunity as a tool for studying epigenetic regulation of cellular differentiation. *Front Genet* 2013; 4:218.
- [3]. Suarez-Alvarez B, Rodriguez RM, Fraga MF, López-Larrea C. DNA methylation: a promising landscape for immune system-related diseases. *Trends Genet* 2012; 28:506–14.
- [4]. Razzouk S, Termechi O. Host genome, epigenome, and oral microbiome interactions: toward personalized periodontal therapy. *J Periodontol* 2013; 84:1266–71.
- [5]. Ueda H, Uchida H. Epigenetic modification in neuropathic pain. *Curr Pharm Des* 2015; 21:849–67.
- [6]. Tollefsbol TO. Advances in epigenetic technology. *Methods Mol Biol* 2011;791:1–10.
- [7]. Schumacher A, Kapranov P, Kaminsky Z, Flanagan J, Assadzadeh A, Yau P, et al. Microarray-based DNA methylation profiling: technology and applications. *Nucleic Acids Res* 2006; 34:528–42.
- [8]. Guan Z, Giustetto M, Lomvardas S, Kim J-HH, Miniaci MC, Schwartz JH, et al. Integration of long-term-memory-related synaptic plasticity involves bidirectional regulation of gene expression and chromatin structure. *Cell* 2002; 111:483–93.
- [9]. Hart AK, Fioravante D, Liu R-YR-Y, Phares GA, Cleary LJ, Byrne JH. Serotonin mediated synapsin expression is necessary for long-term facilitation of the aplysia sensor motor synapse. *J Neurosci* 2011; 31:18401–11.
- [10]. Gregoretti IV, Lee Y-MM, Goodson HV. Molecular evolution of the histone deacetylase family: functional implications of phylogenetic analysis. *J Mol Biol* 2004; 338:17–31.
- [11]. Dekker FJ, van den Bosch T, Martin NI. Small molecule inhibitors of histone acetyltransferases and deacetylases are potential drugs for inflammatory diseases. *Drug Discovery Today* 2014;19:654–60.
- [12]. Lutz BM, Bekker A, Tao Y-X. Noncoding RNAs. *Anesthesiology* 2014; 121:409–17.
- [13]. Huntzinger E, Izaurralde E. Gene silencing by microRNAs: contributions of translational repression and mRNA decay. *Nat Rev Genet* 2011; 12:99–110.
- [14]. Sakai A, Suzuki H. *MicroRNA and Pain*, Springer, Cham, p. 17–39; 2015.
- [15]. Kim SH, Lee SY, Lee YM, Lee YK. MicroRNAs as biomarkers for dental diseases. *Singap Dent J* 2015; 36:18–22.
- [16]. Gomes CC, Gomez RS. MicroRNA and oral cancer: future perspectives. *Oral Oncol* 2008; 44:910–4.
- [17]. Breitling LP, Yang R, Korn B, Burwinkel B, Brenner H. Tobacco-smoking-related differential DNA methylation: 27k discovery and replication. *Am J Hum Genet* 2011; 88:450–7.
- [18]. Smith IM, Mydlarz WK, Mithani SK, Califano JA. DNA global hypomethylation in squamous cell head and neck cancer associated with smoking, alcohol consumption and stage. *Int J Cancer* 2007; 121:1724–8.
- [19]. Saatci C, Caglayan AO, Ozkul Y, Tahiri S, Turhan AB, Dundar M. Detection of p16 promoter hypermethylation in “Maras powder” and tobacco users. *Cancer Epidemiol.* 2009; 33:47–50.
- [20]. Shao C, Sun W, Tan M, Glazer CA, Bhan S, Zhong X, et al. Integrated, genomewide screening for hypomethylated oncogenes in salivary gland adenoid cystic carcinoma. *Clin Cancer Res* 2011; 17:4320–30.
- [21]. Ling S, Rettig EM, Tan M, Chang X, Wang Z, Brait M, et al. Identification of methylated genes in salivary gland adenoid cystic carcinoma xenografts using global demethylation and methylation microarray screening. *Int J Oncol* 2016; 49:225–34.
- [22]. Massart R, Dymov S, Millecamps M, Suderman M, Gregoire S, Koenigs K, et al. Overlapping signatures of chronic pain in the DNA methylation landscape of prefrontal cortex and peripheral T cells. *Sci Rep* 2016; 6:19615.
- [23]. Jones TI, Yan C, Sapp PC, McKenna-Yasek D, Kang PB, Quinn C, et al. Identifying diagnostic DNA methylation profiles for facioscapulohumeral muscular

- dystrophyin blood and saliva using bisulfite sequencing. *ClinEpigenet* 2014; 6:23.
- [24]. Piyathilake CJ, Bell WC, Jones J, Henao OL, Heimburger DC, Niveleau A, et al. Patterns of global DNA and histone methylation appear to be similar in normal, dysplastic and neoplastic oral epithelium of humans. *Dis Markers* 2005; 21:147–51.
- [25]. Chen Y-W, Kao S-Y, Wang H-J, Yang M-H. Histone modification patterns correlate with patient outcome in oral squamous cell carcinoma. *Cancer* 2013; 119:4259–67.
- [26]. Kusumoto T, Hamada T, Yamada N, Nagata S, Kanmura Y, Houjou I, et al. Comprehensive epigenetic analysis using oral rinse samples: a pilot study. *J Oral Maxillofac Surg* 2012; 70:1486–94.