

A Case Study to Check the Efficacy of Agnikarma in Epididymo-Orchitis with Special Reference to Vataja Vriddhi

Dr. Shubhangi Matkar¹, Dr. Nilesh Chavan², Dr. Manoj Sonaje³, Dr. Rameshwar Bhojane⁴

¹PG Scholar, Dept. of Shalya Tantra, Matoshri Asarabai Darade Ayurved College, Yeola, Nashik, Maharashtra, India

²Professor of Dept. of Shalya Tantra, Matoshri Asarabai Darade Ayurved College, Yeola, Nashik, Maharashtra, India

³Professor & HOD, Dept. of Shalya Tantra, Matoshri Asarabai Darade Ayurved College, Yeola, Nashik, Maharashtra, India

⁴PG Scholar, Dept. of Shalya Tantra, Government Ayurvedic College, Nanded, Maharashtra, India

Date of Submission: 15-09-2025

Date of Acceptance: 25-09-2025

ABSTRACT-When epididymis is first inflamed, which is known as epididymitis and later on infection spreads to the testis and then the condition is called epididymo-orchitis.^[7] Symptoms are pain, fever and tenderness in testis. The disease can be correlated with Vridhi Roga in Ayurveda. In present case study patient diagnosed with epididymo-orchitis was treated with Agnikarma. This treatment procedure is mentioned in Sushruta Samhita chikitsa sthan.^[5] After completing all routine investigations, Agnikarma was performed once over the left Angushthamula in a patient diagnosed with epididymo-orchitis. Follow-up assessments were conducted on the third and seventh day post-Agnikarma. The therapy demonstrated a significant reduction in testicular swelling and associated pain. Objective measurements of the right testis size were recorded before and after the treatment, showing clear improvement within seven days.

Keywords: Vriddhi roga, Agnikarma, Angushthamula, epididymo-orchitis,

I. INTRODUCTION

Orchitis is due to infection through blood, lymphatics or epididymis. Inflammation of epididymis with testis is known as epididymo-orchitis.^[1] There are various causes of epididymo-orchitis including viral, filarial, bacterial, sexually transmitted infections and trauma. Pain in the testis with epididymis, fever, tenderness in testis are common features of epididymo-orchitis.^[1] In modern medicine epididymo-orchitis is treated and antibiotics and analgesics with scrotal support. Only if abscess has been formed, surgical intervention is

required in the form of drainage. There is always a chance of some atrophy of the testis.^[7]

Disease is best correlated with the 'Vriddhi' roga in Ayurveda, that is the enlargement of Phalakosha (Scrotum). According to Sushruta there are seven types of Vriddhi Roga.^[2] Among Vriddhi Roga, particularly Vataja condition is best matched with orchitis. Vitiated Doshas pass through the channels of scrotum and cause swelling in Phalakosha.^[2]

Symptoms of Vataja Vriddhi, Vataparipurna Bastimiva Vatataam (Sac filled with air), Parushata (dry and hardness), Animitta Anila Ruja (pain) in the Phalakosha are according to ayurveda.^[3] Agnikarma has been one of the peculiar parasurgical procedure described in Sushruta Samhita. Sushruta has referred Agni in Agropaharaniya Adhyaya as Upayantra and Anushastra.^[4] Agnikarma is one which gives instant relief from pain by balancing local Vata and Kapha dosha without any side effect. Sushruta has mentioned Agnikarma at Angaviparyay (Contralateral) Angushthamula in the management of Vataja and Kaphaja Vriddhi Roga.^[5] Hence for right side of testis the left angosthamula agnikarma was performed in this study. This treatment procedure is described in Sushruta Samhita chikitsa sthan, Vriddhi upadanshashlipada chikitsa adhyaya along with its features.

Hypothesis-Agnikarma done at the contralateral Angushthamula has shown effectiveness in managing epididymo-orchitis

AIMS-1. To study the efficacy of Agnikarma in the management of epididymo-orchitis.

OBJECTIVES

1. To find an alternate, inexpensive, safe and effective management technique for epididymo-orchitis.
2. To assess utility and efficacy of the ancient mode of treatment which is agnikarma in the scientific erato cure epididymo-orchitis.

II. METHODOLOGY

Patient's present illness

A male patient of 49 yrs presented with complains of Swelling and pain at Right scrotal region since one week. Patient gave history of trauma while driving bike. Patient took some conservative treatment from private hospital but didn't get relief. Hence he visited Shalyatantra OPD Matoshri Ayurvedic college, Nashik

- Medicinal history- No history of any major systemic illness
- Surgical history- No any surgical history
- Allergic history- No history of allergy to dust or any drug
- Blood transfusion history- No history of blood transfusion
- Catheterization history- History of catheterization 5years ago
- Family history- No history of any major systemic illness
- Personal history- Issue-Two Female Child
Occupation- Driver
Addiction- Tobacco chewing, SmokingDiet- Mixed diet

General examination

- General condition- Fair, Afebrile
- Blood Pressure- 110/70mm of Hg
- Pulse Rate- 80/min
- No pallor

Systemic examination

- CVS - S1S2 Normal, No murmur
Appetite- Normal Urine- Regular Stool- Regular
No icterus No clubbing of nails
No inguinal lymphadenopathy
- CNS - Conscious and oriented to time, place and person
- RS - AEBE clear, No crept, no wheezing
- P/A - Soft, Non-tender Local examination
- Swelling present over Right scrotal region.
- Bilateral testes separately palpable, tender.
- Coughing impulse- Absent.
- Swelling not reducible.

Investigations

- WBC- 13,030/mm³ BT- 2.17min
Fluctuation test - Negative. Transillumination test - Negative.
- Tenderness - Present Local temperature- Present.
- Hb- 14 mg/dLHIV- Negative
- PLT- 290k/mm³
- VDRL- Negative
- HbsAg- Negative
- BSL (Random)- 98mg/dL
- Sr. Urea- 53mg/dL
- Sr. Creatinine- 1.86mg/Dl .
- CT- 3.45min

Treatment

Instrument used: Red hot lohashalaka

•Purvakarma: (Preoperative) →

- After all routine investigations, Agnikarmawas planned for the patient. →
- Proper informed written consent taken.
- Vertical lengths of Right testes measured with vernier caliper before treatment.

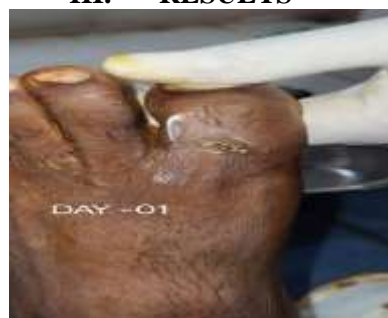•Pradhankarma. (Operative) →

- Patient made to lie on table in supine position.
- Proper position given for Agnikarma on Left greater toes.
- Agnikarma done over left Angushthamula with the help of red hot Lohashalaka.

•Pashchatkarma: (Postoperative) →

- JatyadiGhrit applied at the site of burn and dressing done.
- Scrotal support was given.
- Patient was explained to take care of burn wound.
- Follow up taken on 3rd and 7th day after Agnikarma.

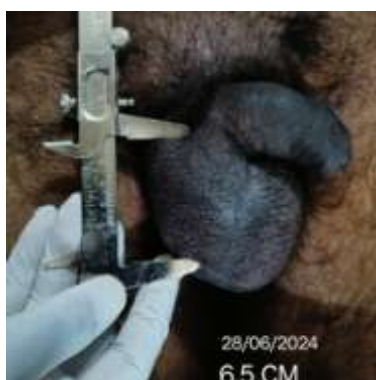
III. RESULTS



After



Before



Before Treatment	Right testis (Vertical length) 7.5cm
After Treatment	Right testis (Vertical length) 6.5cm

I. DISCUSSION

Agnikarmadone on left Angushthamula showed significant decrease of one centimeter in vertical length of swelling of testes and reduced symptoms like pain, local temperature too. Probable mechanism of action in this treatment may be explained as, According to Ayurveda, Usually pain and swelling arise due to blockage of Vata dosha. Vrushan(Scrotum) is the location of Apana Vayu.[6] Due to blockage or prakopa of Apana vayu pain and swelling develops in in the testes. Agnikarma at Angushthamula probably helps in anulomana and shaman of prakupita Apana vayu. Hence pain and swelling in the epididymis and testes are significantly reduced after agnikarma. Positive results obtained in 7 days.

II. CONCLUSION

Pain and swelling are the primary symptoms of Epididymo-orchitis. These symptoms have been observed to significantly subside

following Agnikarma performed using Lohashalaka at the Angushthamula region. The therapeutic effect of Agnikarma is likely attributed to its action of Anulomana and Shamana of the Prakupita Apana Vayu in the scrotal area. Thus, Agnikarma plays a significant role in the management of Epididymo-orchitis.

REFERENCES

- [1]. Dr. Sriram Bhat M, SRB's Manual of Surgery, Jaypee Brothers Medical Publishers, 6.
- [2]. Dr. Anant Ram Sharma, Sushruta Samhita, Chaukhamba publication, Varanasi, Nidansthanadhyay, 2018; 12: 546.
- [3]. Dr. Anant Ram Sharma, Sushruta Samhita, Chaukhamba publication, Varanasi, Nidansthanadhyay, 2018; 12: 547.
- [4]. Dr. Anant Ram Sharma, Sushruta Samhita, Volume I, Chaukhamba publication, Varanasi, Sutrasthanadhyay, 2018; 7, 8: 62-69
- [5]. Dr. Anant Ram Sharma, Sushruta Samhita, Chaukhamba publication, Varanasi, Chikitsasthanadhyay, 2018; 19: 323.
- [6]. Vaidya Harishchandra Singh Kushwaha, Volume II, Chakrapanidatta, Commentator Charak Samhita Chikitsa SthanChaukhamba Orientalia Varanasi, 2020; 28: 10-11.
- [7]. S. Das, A Concise textbook of Surgery, 11th Edition, Jaypee Brothers Medical Publishers, Pg. 1320