International Journal of Pharmaceutical Research and Applications
Volume 10, Issue 4 July-Aug 2025, pp: 736-742 www.ijprajournal.com ISSN: 2456-4494

A Study on Steven Johnson Syndrome: Causes, Symptoms, Diagnosis and Treatment

Author: Ms S Jamuna., Mr G Harish Ganth., Mr A Joyal christopher.
Final year students P.S.V Collegeof Pharmaceutical Science and Research, Krishnagiri – 635108.

Co- author: Ms A Mumtaj Begam
M. Pharm., Department of Pharmacology (Assistant Professor), P.S.V College of Pharmaceutical Science and Research, Krishnagiri – 635108.

Date of Submission: 05-08-2025 Date of Acceptance: 15-08-2025

ABSTRACT
Stevens-Johnson Syndrome (SJS) is a rare but severe hypersensitivity reaction that primarily affects the skin and mucous membranes, representing one end of a spectrum of epidermal necrolysis disorders. It is most frequently induced by medications such as antiepileptics, sulfonamides, and NSAIDs, though infections and idiopathic cases are also recognized. This review comprehensively discusses the epidemiology, etiological factors, immunopathogenesis, clinical course, diagnostic challenges, and therapeutic options associated with SJS. Management requires a multidisciplinary approach, focused on immediate withdrawal of the offending agent, intensive supportive care, wound management. This review aims to synthesize current evidence to enhance clinical recognition, optimize treatment strategies, and highlight areas for future research, including the development of predictive biomarkers, genetic screening (e.g., HLA typing), and novel immunomodulatory treatments.

Key words : Steven Johnson Syndrome, Immunopathogenesis, Immunomodulatory treatments and Keratinocyte apoptosis.

I. INTRODUCTION

Steven-Johnson syndrome (SJS) and Toxic epidermal necrolysis (TEN) are rare, serious hypersensitivity reaction usually caused by drugs or infection, characterized by widespread skin and mucous membrane blistering and detachment[(1)]. Medications are the primary cause of life-threatening mucocutaneous reactions that can result in rare conditions like SJS and TEN. Epidermal necrosis and detachment are common symptoms of these disorder, along with mucous membrane erosions[(2)]. While SJS is a more moderate from, accounting for less than 10% of the BSA, TEN has over 30%. When there is a 10% to 30% stake from BSA involvement, it is labelled as "SJS/TEN overlap"[(3)]. Despite being uncommon, these conditions are classified as dermatological emergencies due to their high mortality rates-up to 48% in TEN- and range between 0.4 and 9.2 cases per million people annually, depending on geographic location andage group[(4)]. Antibiotics, anticonvulsants, NSAIDS and albendazole and some medication can cause these reactions, which are typically caused by drugs. However, they are more likely to trigger these drug-induced responses. In SJS/TEN, numerous internal organ systems, including the pulmonary, gastrointestinal/hepatic, oral, otorhinolaryngologic, gynaecologic, genitourinary, and renal systems, are impacted in addition to the eyes and skin. There are also serious emotional repercussions, and social work and nursing care are essential to these patients' recovery. An outline of the organ systems implicated in SJS/TEN and how a multidisciplinary team may offer these patients the best care possible are the goals of this review[(5)].

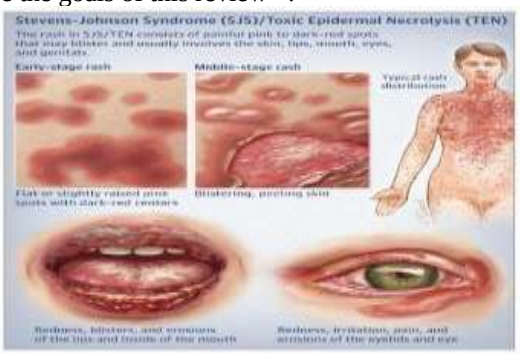

Figure 1. visual representation of Steven Johnson syndrome (SJS)

II. AIM & OBJECTIVES

To provide a comprehensive overview of Stevens–Johnson Syndrome, including its etiology, pathophysiology, clinical features, diagnostic

International Journal of Pharmaceutical Research and Applications
Volume 10, Issue 4 July-Aug 2025, pp: 736-742 www.ijprajournal.com ISSN: 2456-4494

approaches, management strategies, and prognosis. To compile and critically evaluate recent research findings to enhance understanding and improve patient outcomes in SJS.

OBJECTIVES:

1. Etiology & Risk Factors – Common drugs, infections, and genetic predispositions.
2. Pathophysiology – Immune mechanisms, apoptotic pathways, and key mediators.
3. Clinical Features – Prodrome, mucocutaneous lesions, complications.
4. Diagnosis – Criteria, differential diagnosis, and role of biopsy.
5. Management – Supportive care, pharmacologic options, and multidisciplinary approach.

III. ETIOLOGY

SJS is mostly caused by the immune response produced by certain medications and also caused by some infections.

1. MEDICATIONS:

A short list of medications which causes SJS are follows as;

- anticonvulsants like lamotrigine, carbamazepine, phenytoin and phenobarbitone
- oxicam class non – steroidal anti-inflammatory drugs (NSAIDs), acetaminophen
- penicillin antibiotics like amoxicillin bacampicillin
- cephalosporins like cefaclor and cephalexin
- quinolines like ciprofloxacin, norfloxacin and ofloxacin
- tetracyclines like doxycycline and minocycline[6-9]

2. INFECTIONS:

There are two main categories which gets associated with SJS such as Viral infections and Bacterial infections

- **VIRAL INFECTIONS:** Hepatitis, Herpes,HIV,Influenza,Mumps, Pneumonia
- **BACTERIAL INFECTIONS:** Brucellosis, Diphtheria, Mycoplasma pneumoniae, Tuberculosis

FACTORS THAT CAUSE RISK OF SJS:

- Bone marrow transplant
- Chronic diseases of joints and connective tissue
- Cancer

3. IDIOPATHIC CAUSE :

In some patients, the cause for SJS remains unknown even after thorough evaluation and examination. Several hypotheses have been exist like;

- Over the counter medications (OTC).
- Contaminants or excipients in medications.
- Undiagnosed auto immune disease[10]

IV. PATHOPHYSIOLOGY

SJS and TEN are immune-mediated hypersensitivity reactions usually linked to medication, but that can also cause by infections malignancies. The majority of these are usually drug related or prescribed. Many of these are antibiotics that people are usually drugged into prescribed – most commonly sulphonamides, anti-vulnerability drugs like carbamazepine and NSAIDs. Mirtazapine, TNF-alpha inhibitors and cocaine are also other potential triggers.

The major component of these disease processes is a delayed-type IV hypersensitivity response, mediated by CD8+ cytotoxic T cells. CD8+T cells activate T cell recognition by specific HLA molecules and trigger the massive keratinocyte apoptosis via the FAS/Fas ligand pathway and possibly through cytotoxic protein mechanisms such as perforin and granulysin.These are also theories of retinoid toxicity that suggest some drugs may interact with endogenous radicals resulting in liver injury.

The pathophysiology is still unclear but SJS/TEN is a disease state which is characterized not just by genetic susceptibility, but a complex interaction between- mediated cytotoxicity and the drug or infection triggers. The understanding of these immune mechanisms has also guided emerging treatment strategies targeting immune modulation, such as TNF-alpha inhibitors**,** IVIG**,** and cyclosporine, aiming to halt disease progression early[11].

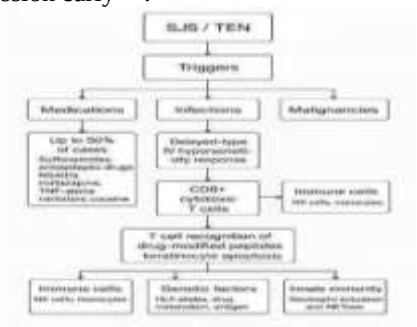

Figure 2. Pathogenesis of SJS leading to skin damage.

International Journal of Pharmaceutical Research and Applications
Volume 10, Issue 4 July-Aug 2025, pp: 736-742 www.ijprajournal.com ISSN: 2456-4494

V. SIGNS AND SYMPTOMS

I. CUTANEOUS:

- Photosensitivity,
- Cutaneous scars,
- Alopecia.
- Nail loss

II. OCULAR:

- Dry eyes, Pain
- Eyelid dysfunction
- Photophobia &Visual impairment

III. ORAL MUCOUS MEMBRANE:

- Dryness, Dental caries,
- Ulceration,
- Permanent loss of tongue papillae[12]

IV. OTORHINOLARYNGOLOGIC:

- Dysphonia,
- Impaired swallowing,
- External auditory canal stenosis.

V. PULMONARY:

- Cough &Wheezing,
- Obstructive lung disease.

VI. GYNAECOLOGICAL / GENITO URINARY:

- Subfertility or infertility (secondary to menstrual abnormalities),
- Urethral erosions and strictures,
- Permanent loss of tongue papillae[12]

VI. DIAGNOSIS

Diagnosis is based on the information from the history and physical examination. It can be done by different tools like skin biopsy, laboratory evaluation and imaging.

1. SKIN BIOPSY:

It is a crucial diagnostic tool used to confirm SJS and differentiate it from other dermatological disorders especially and when clinical features are unclear or overlapping with other dermatological disorders (e.g., erythema multiforme and bullous pemphigoid)[12].

2. LABORATORY EVALUATION:

This test will evaluate internal organ involvement and monitors the complications of the disease. It can be done by basic laboratory tests

BASIC LABORATORY TESTS:

TEST	PURPOSE	FINDINGS IN SJS
Complete blood count (CBC)	Detects inflammation and infection	Leukocytosis (↑ WBC) Possible anaemia-eosinophilia (in drug induced cases)
Liver function tests (LFTs)	Drug induced liver injury	↑AST/ALT, ↑bilirubin
Renal function tests	Monitors acute kidney injury	↑ creatinine, ↑ urea

Note: WBC - White blood cells, AST -Aspartate Amino Transefrase, ALT -Alanine AminoTransferase, Na -Sodium ions and K - Potassium ions.

Table -1. Laboratory tests for SJS.



Figure 3. Diagnosis method to determine the presence of disease.

3. IMAGING:

This study are not central to the diagnosis. However they may used in specific conditions like evaluation of organ complications (especially lungs) and Monitors infection or sepsis.

IMAGING MODALITY	PURPOSE IN SJS
Chest X- ray (CXR)	Pneumonia or acute respiratory distress syndrome (ARDS) - common if mycoplasma pneumoniae is suspected trigger
Ultrasound (abdomen /kidneys)	Evaluates renal, liver ansd spleen involvement in systemic drug reaction
MRI brain (rare)	Only if neurological symptoms is suspected.

Table-2. Detection of sjs by imaging methods[12-15]

International Journal of Pharmaceutical Research and Applications
Volume 10, Issue 4 July-Aug 2025, pp: 736-742 www.ijprajournal.com ISSN: 2456-4494

VII. TREATMENT

The most crucial step in the acute phase of SJS/TEN suspicion is to immediately stop taking the suspected medication. This can reduce mortality.

1. INTEGUMENT:

SJS/TEN experienced long-term cutaneous sequelae, including scars, milia, urticaria, and post inflammatory skin alterations. In order to minimize fluid loss, avoid infection due to microbial colonization, and improve re-epithelialization, a suitable dressing is applied if the dermis is exposed[16]. Certain symptomatic therapies are available for SJS of the skin; they are used as

- Skin lesion care
- Sunscreens

a. **SKIN LESION CARE:** The primary treatments for SJS and TEN symptoms are comparable to those for burns. This entails regulating the room temperature, handling aseptic and antiseptic materials carefully, keeping the environment aseptic and clean, and staying away from adhesives.

b. **SUNSCREEN:** Sunblock's are advised as a protective agent against sunlight, and laser treatment may be administered to minimize skin pigmentation alteration and to improve cosmetic appeal[17].

2. OCULAR INVOLVEMENT:

The eye undergoes unrecoverable differences that may eventually affect in blindness. Aggressive lubrication, prudent topical corticosteroid eye drop use, antibiotic eye drop infection forestalment, and amniotic membrane transplantation[16]. Certain symptomatic therapies are available for SJS of the eyes ; they are used as

- Ophthalmic topical antibiotics
- Ophthalmic topical cyclosporin

a. **OPHTHALMIC TOPICAL ANTIBIOTICS:** Eye drops containing chloramphenicol are occasionally recommended during the acute phase of the illness. The topical antimicrobial can also be administered as an eye drop that contains 0.1% dexamethasone and chloramphenicol.

b. **OPHTHALMIC TOPICAL CYCLOSPORINE:** Topical drops of 0.5% moxifloxacin, 0.5% cyclosporine, and 0.1% dexamethasone applied twice daily have demonstrated positive outcomes in treating SJS eye involvement[17].

3. ORAL INVOLVEMENT:

In the acute stage, oral mucosal involvement happens in as many as 100% of SJS/TEN patients and shows formation of sores and painful inflammation in the mucous membrane. Due to discomfort in the oral mucosa and difficulties swallowing, a significant portion of patients will need nasogastric tube feeding during the acute period[16]. Some the drugs used to treat oral symptoms are:

a. **TOPICAL ANESTHETICS:** To relieve pain during eating, drinking, and oral hygiene

- Lidocaine viscous 2%**:** used as a mouth rinse or applied directly
- Benzocaine gel (use with caution due to allergy risk)

b. ANTI ULCER AGENTS:

- Sucralfate suspension is used to coat ulcer ,sores and promotes healing[18]

4. GENITAL INVOLVEMENT:

Urinary tract involvement occurs due to the extension of mucosal damage to the urethra**,** bladder**,** or surrounding structures.

- vaginal erosions with mucosal detachment
- Menstrual blood retention in extreme cases if vaginal opening is occluded.
- Painful lesions on scrotum and penis.
- Erectile dysfunction [19].

Certain symptomatic therapies are available for SJS of the eyes ; they are used as

a. Local hygiene and wound care
b. Barrier Agents / Emollients

a. **LOCAL HYGIENE AND WOUND CARE:** Gentle cleansing with saline or mild antiseptic (e.g., chlorhexidine**)** to prevent infections.

b. **BARRIER AGENTS / EMMOLIENTS:** Petrolatum jelly, zinc oxide cream, or lanolin can be used to keep tissues moist and separated. These reduce friction and promote healing[20].

5. RENAL INVOLVEMENT :

It leads to Acute Kidney Injury (AKI), Hematuria and Proteinuria, Postrenal Obstruction (Rare),

International Journal of Pharmaceutical Research and Applications
Volume 10, Issue 4 July-Aug 2025, pp: 736-742 www.ijprajournal.com ISSN: 2456-4494

Chronic Kidney Disease (CKD)[21-22]. Some of the measures to treat kidney failure are;

- Restoring fluids and hydration,
- Stopping the intake of the culprit and harmful drugs,
- Check for urine blockage.

a. RESTORING FLUIDS AND HYDRATION: Giving IV fluids (like saline) to restore blood flow to kidneys [23].

b. **STOPPING THE INTAKE OF CULPRIT AND HARMFUL DRUGS :** Avoid NSAIDs, contrast dyes, and some antibiotics which may produce kidney failure[22]

6. OTORHINOLARYNGOLOGIC INVOLVEMENT:

The otorhinolaryngologic involvement in SJS covers ear, nose, oral cavity, larynx and pharynx with clinical side effects.

a. **NOSE (NASAL CAVITY)**: Crusting, nasal pain, obstruction due to mucosal erosions. Some drugs used to treat

- Antibiotic ointments (e.g., mupirocin) to prevent secondary infection.
- Topical corticosteroids (nasal spray) if needed[23].

b. **ORAL CAVITY:** Painful ulcers on lips, buccal mucosa, tongue and inability to eat or drink. Some drugsused to treat

- Saline or antiseptic mouthwashes (e.g., chlorhexidine).
- Analgesic mouthwashes (e.g., benzylamine hydrochloride)[24].

VIII. GASTRO INTESTINAL INVOLVEMENT:

In the initial phase of SJS/TEN, there have been isolated cases of death of body tissue of the stomach, and intestine, which results in death of the tissues in the intestine due to the lack of blood supply which showup as diarrhea, vomiting blood and extreme abdominal pain[25-26]. It can be treated by the oesophageal dilation[27].

IX. CONCLUSION

Stevens-Johnson syndrome (SJS) is an uncommon but dangerous immune-mediated hypersensitivity reaction that is frequently caused by infections like Mycoplasma pneumoniae or drugs like NSAIDs, sulphonamides, antiepileptics, and allopurinol. SJS, which is characterized by mucosal involvement and epidermal necrosis, has a high risk of morbidity and death if it is not identified and treated. The most important treatment is still supportive care, which includes careful wound care, electrolyte and hydration management, proper nutrition, efficient pain management, infection prevention, and thermoregulation. Non-pharmacological interventions are essential in stabilizing the patient and facilitating tissue healing. Involvement of a multidisciplinary team—including dermatologists, ophthalmologists, ENT specialists, pulmonologists, urologists, psychiatrists, and critical care experts—is crucial to manage acute complications and prevent long-term sequelae.

REFERENCE

[1]. Rohini Arora, Rajesh K Pande, Shikha Panwar, Vivek Gupta: Drug-related Steven-Johnson Syndrome and Toxic Epidermal Necrolysis: A Review; 2021 May. 10.5005/jp-journals-10071-23826

[2]. Tyagi S, Kumar S, Kumar A, Singla M, Singh A. Stevens-Johnson Syndrome-A life threatening skin disorder: A review. J Chem Pharm Res [Internet]. 2010 [cited 2025 Jul 29];2(2):618–26. https://10.35629/5252-0506427434

[3]. Shah H, Parisi R, Mukherjee E, Phillips EJ, Dodiuk-Gad RP. Update on Stevens–Johnson Syndrome and Toxic Epidermal Necrolysis: Diagnosis and Management. American Journal of Clinical

[4]. Dermatology. 2024 Sep 15; https://doi.org/10.1093/bjd/ljae321

[5]. Hama N, Aoki S, Chen CB, Hasegawa A, Ogawa Y, Vocanson M, et al. Recent progress of Stevens- Johnson syndrome/toxic epidermal necrolysis: Diagnosis criteria, pathogenesis and therapy. British Journal of Dermatology. 2024 Aug 14; https://doi.org/10.1093/bjd/ljae321

[6]. Gupta L, Martin A, Agarwal N, D'Souza P, Das S, Kumar R, et al. Guidelines for the management of Stevens–Johnson syndrome/toxic epidermal necrolysis: An Indian perspective. Indian Journal of Dermatology, Venereology, and Leprology. 2016;82(6):603 10.4103/0378-6323.191134

[7]. Arndt JW, Gu J, Jaroszewski L, Schwarzenbacher R, Hanson MA, Lebeda

International Journal of Pharmaceutical Research and Applications
Volume 10, Issue 4 July-Aug 2025, pp: 736-742 www.ijprajournal.com ISSN: 2456-4494

FJ, et al. The Structure of the Neurotoxin-associated Protein HA33/A from Clostridium botulinum Suggests a Reoccurring β- Trefoil Fold in the Progenitor Toxin Complex. Journal of Molecular Biology. 2005 Mar;346(4):1083–
[8]. 93. https://doi.org/10.1016/j.jmb.2004.12.039
[9]. Stevens-Johnson Syndrome - Causes, Symptoms, Diagnosis, Treatment, Prevention & Prognosis [Internet]. Medindia. https://www.medindia.net/health/conditions/stevens-johnson- syndrome.htm
[10]. Stevens-Johnson Syndrome (SJS): Causes, Rash & Treatments [Internet]. Cleveland Clinic. 2023 [cited 2025 Jul 24].https://share.google/LFAlXgUARUhxz0O9p
[11]. Rossiaky D. Stevens-Johnson Syndrome Overview [Internet]. Healthline. Healthline Media; 2022 [cited 2025 Jul 24]. https://www.healthline.com/health/stevens-johnson- syndrome#causes
[12]. Roujeau JC, Stern RS. Severe Adverse Cutaneous Reactions to Drugs. New England Journal of Medicine. 1994 Nov 10;331(19):1272–85. http://10.1056/NEJM199411103311906
[13]. Drug hypersensitivity: classification and clinical features. Immunol Allergy Clin North Am. 2004 Nov;24(4):373–397. http://10.1016/j.iac.2004.06.008
[14]. Shah H, Parisi R, Mukherjee E, Phillips EJ, Dodiuk-Gad RP. Update on Stevens–Johnson Syndrome and Toxic Epidermal Necrolysis: Diagnosis and Management. American Journal of Clinical Dermatology. 2024 Sep 15; https://doi.org/10.1007/s40257-024-00889-6
[15]. Schwartz RA, McDonough PH, Lee BW. Stevens-Johnson syndrome: a review of current concepts. Am J Clin Dermatol. 2013;14(6):475–493. https://doi.org/10.1007/s40257-013- 0046-1
[16]. U.S. National Library of Medicine – MedlinePlus. Stevens-Johnson syndrome. https://medlineplus.gov/ency/article/000855.htm
[17]. Bastuji-Garin, S., et al. (2000).SCORTEN: a severity-of-illness score for toxic epidermal necrolysis. Journal of Investigative Dermatology, 115(2), 149–153. https://doi.org/10.1046/j.1523-1747.2000.00061.x
[18]. Shanbhag SS, Chodosh J, Fathy C, Goverman J, Mitchell C, Saeed HN. Multidisciplinary care in Stevens-Johnson syndrome. Therapeutic Advances in Chronic Disease. 2020 Apr;11:2040622319894469. 10.1177/2040622319894469
[19]. Purnamawati S, Febriana SA, Danarti R, Saefudin T. Topical treatment for Stevens-Johnson syndrome and toxic epidermal necrolysis: a review. Bali Med J. 2016 Aug 9;5(1):82-90. https://10.15562/bmj.v5i1.274
[20]. Creamer D et al. (2016). Management of Stevens–Johnson Syndrome/Toxic Epidermal Necrolysis: British Association of Dermatologists Guidelines. BrJDermatol.2016;174(6):1194–
[21]. 1227. https:// 10.1111/bjd.14530
[22]. Reisman Y et al. (2007). Genital involvement in toxic epidermal necrolysis: description of a case and review of the literatre.J Eur Acad Dermatol Venereol. 2007;21(7):957–961. https://10.1111/j.1468- 3083.2007.02207.x
[23]. Pereira FA et al. (2007) Recap. Toxic epidermal necrolysis. J Am Acad Dermatol.https:// 10.1016/j.jaad.2006.04.048
[24]. Hung CC et al. (2009).“Acute renal failure and its risk factors in Stevens–Johnson syndrome and toxic epidermalnecrolysis.AmJNephrol..2009;29(6):633–638. https:// 10.1159/000195632
[25]. Lee TH et al. (2018)** – Chen YC et al. (2018). the influence of acute kidney injury on the outcome of steven - johnson syndromeand toxic epidermal necrolysis: the prognostic value of KDIGO sraging. PLOS ONE. 2018;13(9):e0203642. https://10.1371/journal.pone.0203642
[26]. Yang YW, Chen WC, Chuang YW, et al. Acute renal failure and itsrisk factors in steven johnson syndrome and toxic epidermal necrolysis. Dermatology.

2009;218(2):131–138.
https://10.1159/000179357

[27]. Bequignon E, Duong TA, Sbidian E, Valeyrie-Allanore L, Ingen-Housz-Oro S, Chatelin V, Coste A, Wolkenstein P, Chosidow O, Papon JF. Steven johnson syndrome and toxic epidermal necrolysis: Ear, nose,and throat description at acute stage and after remission. JaMA Dermatol. https://10.1001/jamadermatol.2014.4844

[28]. U.K. guidelines for the management of Stevens–Johnson syndrome/toxic epidermal necrolysis in adults. British journal of dermatology. 2016 Jun;174(6):1194–1227.

[29]. https://10.1111/bjd.14530

[30]. Oh D, Choung RS, Razonable RR, et al. Gastrointestinal involvement in Stevens-Johnson syndrome and toxic epidermal necrolysis. World Journal of Gastrointestinal Endoscopy, 2019 Feb 16; 11(2): 115–125. https://10.4253/wjge.v11.i2.115

[31]. Zhou Q, Zhang L, Wang J, et al. Gastrointestinal and hepatobiliary involvement in Stevens- Johnson syndrome and toxic epidermal necrolysis: a retrospective study of 41 cases. Scandinavian Journal of Gastroenterology, 2019; 54(10): 1241–1247. https://10.1080/00365521.2019.1652742